

CHAPTER 9

CIRCUMCISION METHODS FOR ADOLESCENT BOYS AND MEN



This chapter provides information on the following:

- preparations for the circumcision procedure
- local anaesthesia for male circumcision
- step-by-step process for three conventional methods of surgical circumcision for adolescent boys and men: forceps-guided, dorsal slit and sleeve resection
- variations in technique necessary when there is phimosis or scarring of the frenulum
- devices used for male circumcision

9.1. INTRODUCTION

By the time the client is in the procedure room, several important services and preoperative actions will have already been undertaken. The client has been found eligible for circumcision at the clinic or facility level and an appropriate method has been selected (as applicable). The client—or his parent(s)/guardian(s)—has provided consent/assent (see Box 9.1). In addition, the necessary equipment and supplies have been prepared for the circumcision procedure.

Box 9.1. Reminder on consent/assent

Even after all preparations are complete, **a client may withdraw consent/assent at any time**. While the provider can try to reassure any client who expresses doubt about the procedure, ultimately, whether the client is an adult or adolescent, the provider should respect the client's decision.

There are several different methods for conventional or device-based surgical circumcision. The most appropriate method for a particular client depends on many factors:

- capacity of the clinic or facility to provide the method, that is, the skill level of the provider who will be doing the procedure and the availability of supplies and equipment required;
- medical eligibility of the client for the method, based on a focused history and physical examination, including a detailed examination of the penis and assessment of penile development; and
- client's preferred method (depending on medical eligibility), as feasible.

This chapter describes three widely used conventional or device-based surgical circumcision methods for adolescent boys and men: forceps-guided, dorsal slit and sleeve resection. These surgical techniques were also described in the 2009 edition of this *Manual for male circumcision under local anaesthesia and HIV prevention services for adolescent boys and men (Manual)*. At that time, these techniques were chosen on the basis of extensive experience worldwide and their use in three randomized controlled trials of male circumcision in Kenya, South Africa and Uganda. In this edition of the *Manual*, the three techniques have been slightly modified because of the experience of more than 10 million adult and adolescent male circumcisions performed in East and Southern Africa.

Male circumcision device methods recommended by the World Health Organization (see Box 9.2) are also efficacious, safe and acceptable methods of male circumcision among healthy men in the context of HIV prevention (1). Devices are also prequalified through the World Health Organization for quality assurance. This *Manual* provides only limited information on devices. Providers who perform male circumcision using device-based surgical circumcision methods should know which methods are recommended and receive manufacturer-accredited training for the proper use of a particular device method. Thereafter, they should also consult the manufacturer's most recent instructions for use of the device because device-based methods are relatively new and manufacturer's instructions for use frequently change to keep up to date with user experience.

Box 9.2. Devices prequalified by the World Health Organization

For current information about male circumcision device recommendations and those prequalified by the World Health Organization, visit these webpages:

<http://www.who.int/hiv/topics/malecircumcision/en/>

http://www.who.int/diagnostics_laboratory/evaluations/PQMCdevices_list/en/

9.2. SAFE SURGERY

9.2.1. Key safety principles for male circumcision services

Providers doing male circumcision procedures should keep the following in mind:

- Male circumcision is an elective procedure performed on a healthy adolescent boy or man for partial protection from HIV.
- Male circumcision presents a different situation from performing a medically necessary procedure on someone who is ill, when the risk of possible adverse events is balanced against harm caused by the illness (or resulting from not doing the procedure).
- Client safety is a top priority in the context of male circumcision as part of a comprehensive HIV prevention strategy.

To ensure that client safety is a top priority, the provider doing the male circumcision, and the provider's managers or supervisors, should apply the following principles:

- **Competence in basic surgical skills is key.** The most important component of safe surgery is having proper training in basic surgical skills (see Chapter 8) and in one or more of the specific methods described in Chapter 9.
- **Necessary supplies, equipment and other resources are available and ready for use.** These include materials needed for providing safe, appropriate and routine services, and managing any adverse events.
- **Allowing enough time is critical.** Overly hurried surgery is associated with an increase in adverse events. Most surgical methods require about 20–30 minutes per procedure. Allowing adequate time for safe surgery can be a problem when there is pressure to undertake a large number of procedures, but the provider doing the procedure must always put the client's safety first. This is particularly important if there are difficulties in stopping bleeding during a procedure.
- **Proper sterile technique and infection prevention save lives.** Anyone who touches the client during the procedure or comes into contact with any of the supplies, equipment, materials or waste from the screening or examination should be trained and skilled in performing standard infection prevention practices, as well as those practices specific to male circumcision. These specific practices are in the procedures regarding actions to take before, during and after the male circumcision (see Chapters 8–10). They are also presented in more detail and in a broader context in Chapter 5.
- **Providers should know the limits of their expertise.** The provider doing the circumcision procedure should know his or her limits. Everyone on the team should work to create an environment where those doing the circumcision are supported and encouraged to seek advice or backup at any time. If something goes wrong, the provider doing the procedure should let others know about it and receive encouragement to get another trained provider to help—and not try to hide the problem. Problems are much easier to manage in a supportive environment, where asking for help is encouraged and where there is backup. Adverse events are often made worse by panicked attempts to overcome problems without help.

- **It is safer to have a trained assistant.** Having a trained assistant helps to keep the surgery safe for the client, reduces the chance of the sterile area becoming contaminated and reduces stress if there is any difficulty with the procedure.
- **Use the World Health Organization's safe surgery checklist to improve client safety.** Using the World Health Organization's safe surgery checklist has improved the safety of surgery throughout the world. A version of this checklist was adapted for male circumcision and is in Chapter 7. The use of the checklist is particularly important in any clinic or facility shared by male circumcision services and other services, such as family planning or general surgery, where other types of surgery are done, and, particularly, where other types of surgery are done in the same procedure room as the one used for male circumcision.

Adverse events, while rare, can negatively influence the uptake of male circumcision services in the community, particularly if these incidents are not appropriately managed.

9.2.2. Circumcision-specific skills

The provider who is doing the procedure should be trained and skilled in basic surgical skills (see Chapter 8) and in skills specific to the method of male circumcision that he or she will be performing. These are highlighted below and presented in more detail in this chapter. The basic surgical skills are the following:

- Prepare the skin and drape the client before the procedure (see Section 9.3).
- Give injectable local anaesthesia using subcutaneous ring block or dorsal nerve block, or both (see Section 9.4).
- Retract the foreskin and manage adhesions (see Section 9.5.1).
- Mark the line for circumcision (see Section 9.5.2).
- Realign tissue and skin after the procedure (see Section 9.5.3).
- Avoid damaging the urethra by having proper understanding of the anatomy of the frenulum and knowing the relationship between the frenulum and the underlying urethra (see Section 9.6.1).
- Perform the forceps-guided method of circumcision (see Section 9.6.1).
- Perform the dorsal slit method of circumcision (see Section 9.6.2).
- Perform the sleeve resection method of circumcision (see Section 9.6.3).
- Dress the wound (see Section 9.7).
- Ensure that there is good recordkeeping and reporting (see Section 9.8).

9.3. SKIN PREPARATION AND DRAPING

9.3.1. Skin preparation

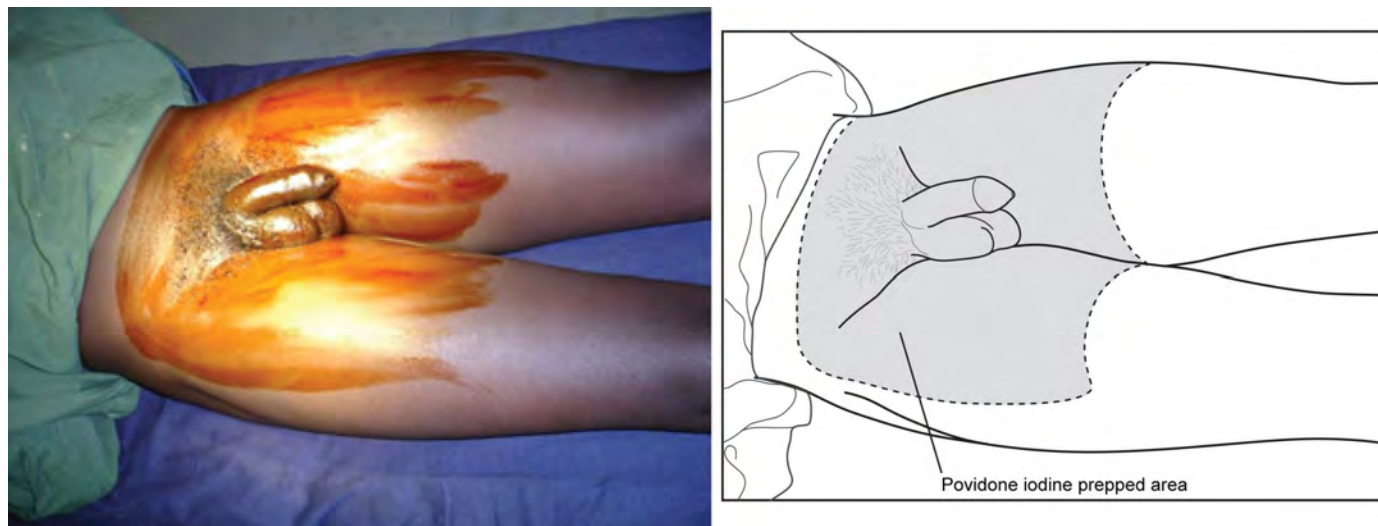
Before the client's skin is prepared, his genital area should be washed with soap and clean water to remove all visible dirt and debris. If he has not done so at home, this should be done at the clinic or facility. Cleaning is an essential step, as antiseptics will not be effective without thorough cleaning. Cleaning may be done with clean exam gloves. Prepare the skin with povidone iodine aqueous solution, starting with the glans and the shaft of the penis, and then moving out to the periphery (see Fig. 9.1). If the client has a history of allergy to iodine, use an alternative solution, such as chlorhexidine gluconate. Cleaning should be gentle. Holding the penis with a gauze swab, retract the foreskin to clean the glans. If there are adhesions, then give the client anaesthesia at this time; go back and clean the glans and coronal sulcus after the anaesthesia has worked (that is, after it has taken effect).

The areas prepared with antiseptic include the penis, scrotum, adjacent areas of the thighs and lower part of the abdomen (suprapubic area), so there is no risk that the provider doing the procedure will touch unprepared skin. Repeat the

procedure so that the skin area is prepped two more times (three total). The cleaned penis should not be placed on skin that is not prepared (for example, abdomen or thigh).

After the third wash, the wet antiseptic solution should remain on the skin for at least two minutes and allowed to dry.

Fig. 9.1. Preprocedure skin preparation with povidone iodine^a

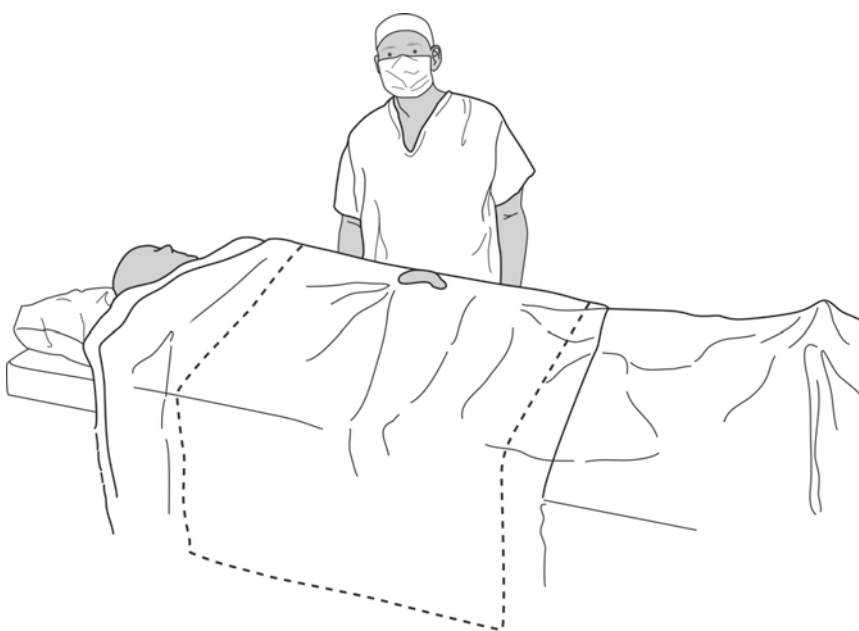
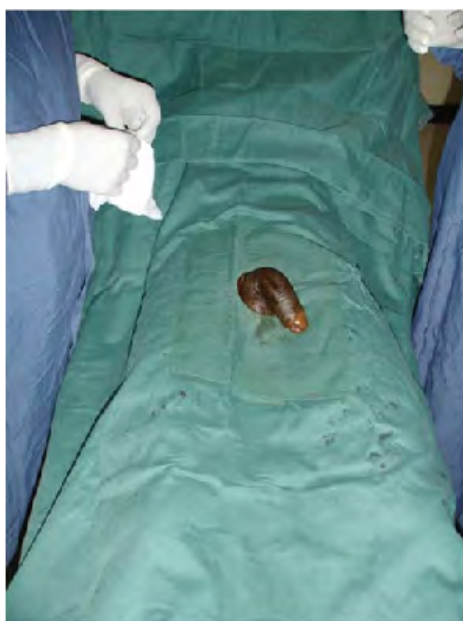

^a Photograph © R. Bailey, Kisumu Project

9.3.2. Draping

Draping provides a sterile operative field and helps prevent wound contamination. Before covering the client with sterile drapes, the provider doing the procedure (and any trained assistant) should carry out hand preparation, put on a sterile apron and put on sterile gloves. Only the operative area and the area where the anaesthesia will be administered should be left uncovered. A single drape with a hole for the penis (O-drape) (see Fig. 9.2) is better than four drapes secured with towel clips. The drape should cover the entire knee-to-chest area to provide an adequately large sterile field. The drape edges that hang below the procedure table are not sterile.

Fig. 9.2. Draping for male circumcision^a



^a The minimum sterile field is shown by the dotted lines in the drawing.

9.4. LOCAL ANAESTHESIA

When using a conventional surgical method, injection of a local anaesthetic agent(s) is recommended. Local anaesthesia is simpler, safer and less expensive than general anaesthesia; also, the client can return home on the same day as the procedure. There are two possible techniques for injecting penile local anaesthesia: subcutaneous ring block or dorsal nerve block. These techniques may be supplemented by local infiltration at the frenulum.

Topical anaesthetic cream can be used for circumcision with some device methods (see the manufacturer's instructions for use for the specific device).

9.4.1. Dose of injectable local anaesthetic agent(s)

The local anaesthetic agent(s) most often used is plain lidocaine/lignocaine 1% or 2%, alone or in combination with plain bupivacaine 0.25% or 0.5%. Bupivacaine may be used in clients aged 10 years and older, regardless of weight. The selection of drug concentration is typically made by the ministry of health for the overall national male circumcision programme; thus, providers may not have a choice about whether to use 1% versus 2% lidocaine/lignocaine or 0.25% versus 0.5% bupivacaine. If there is a choice (particularly, if the client is small), it may be better to use the lower concentration—such as 1% lidocaine/lignocaine with or without 0.25% bupivacaine—because this will allow for a reserve of volume to be available if a repeat injection is needed. Also, with this approach, there is less risk of exceeding the maximum dose. The disadvantage of a lower concentration is that it takes longer to work, and the provider doing the procedure must allow time for the anaesthesia to work.

Both lidocaine/lignocaine and bupivacaine are amide local anaesthetic agents and have similar central nervous system toxicity and cardiac toxicity—although bupivacaine has higher cardiac toxicity than lidocaine/lignocaine. Because the toxic effect is the same for these two agents, their toxicity will be additive when combined. The maximum dose of lidocaine/lignocaine that can safely be given alone is 3 mg/kg of body weight. Bupivacaine is more potent, and the maximum dose that can be given is 1.5 mg/kg of body weight—although use of bupivacaine alone is not recommended. The advantage of lidocaine/lignocaine is that it works rapidly (fast onset). Bupivacaine is more expensive than lidocaine/lignocaine and takes longer to work, but the anaesthesia lasts longer. Combinations of lidocaine/lignocaine and bupivacaine have been used in several million male circumcisions in East and Southern Africa, with dosage in accordance with the *Adverse event action guide, 2nd edition (Guide)*. This *Guide* gives the maximum recommended dose of lidocaine/lignocaine combined

with bupivacaine as 2 mg/kg of lidocaine/lignocaine and 0.5 mg/kg of bupivacaine (2). Tables 9.1–9.4 give examples of starting volumes and maximum volumes, and these tables are helpful guides to ensure that the maximum dose is not exceeded. It is good clinical practice to initially administer a starting dose and move to the maximum dose *only* if needed.

Table 9.1. Maximum doses of lidocaine/lignocaine (1%) local anaesthetic agent(s)

SAFE LOCAL ANAESTHETIC DOSING—STARTING ^a AND MAXIMUM ^b VOLUMES 1% LIDOCAINE/LIGNOCAINE		
Weight in kg	Starting volume	Maximum safe volume
20–29 kg ^c	4 mL	Additional 2 mL to TOTAL of 6 mL
30–39 kg	6 mL	Additional 3 mL to TOTAL of 9 mL
40–50 kg	8 mL	Additional 4 mL to TOTAL of 12 mL
More than 50 kg	10 mL	Additional 5 mL to TOTAL of 15 mL
^a Starting dose of lidocaine/lignocaine is 2 mg/kg. ^b Maximum safe dose of lidocaine/lignocaine is 3 mg/kg. ^c For those weighing less than 30 kg, use 5 mL syringe so that volumes can be measured accurately. Starting volume is usually adequate; increase to <i>maximum</i> volume (dose) only if it is required for pain control up to the <i>maximum</i> .		
WARNING: Lidocaine/lignocaine with adrenaline (lidocaine/lignocaine with epinephrine) or bupivacaine with adrenaline (bupivacaine with epinephrine) should never be used for male circumcision surgery because of the risk of ischaemia (vessel constriction) of the whole penis, particularly if the penis is small. Also, the use of lidocaine/lignocaine with adrenaline (lidocaine/lignocaine with epinephrine) or bupivacaine with adrenaline (bupivacaine with epinephrine) may delay the onset of bleeding from blood vessels that require ligation or diathermy.		

Source: (2)

Table 9.2. Maximum doses of lidocaine/lignocaine (1%) and bupivacaine (0.25%) local anaesthetic agents

SAFE LOCAL ANAESTHETIC DOSING—STARTING ^a AND MAXIMUM ^b VOLUMES MIXTURE OF 1% LIDOCAINE/LIGNOCAINE AND 0.25% BUPIVACAINE 1:1 MIXTURE (EQUAL VOLUMES OF EACH)		
Weight in kg	Starting volume ^c (1:1 mixture)	Maximum safe volume (1:1 mixture)
20–29 kg	3 mL of each (6 mL total)	Additional 1 mL of each drug to TOTAL of 8 mL (maximum 4 mL of each)
30–39 kg	4 mL of each (8 mL total)	Additional 2 mL of each drug to TOTAL of 12 mL (maximum 6 mL of each)
40–50 kg	5 mL of each (10 mL total)	Additional 3 mL of each drug to TOTAL of 16 mL (maximum 8 mL of each)
More than 50 kg	5 mL of each (10 mL total)	Additional 5 mL of each drug to TOTAL of 20 mL (maximum 10 mL of each)
<p>^a Starting dose of lidocaine/lignocaine is 1.5 mg/kg and bupivacaine is 0.3 mg/kg. ^b Maximum safe doses of lidocaine/lignocaine is 2.0 mg/kg and bupivacaine is 0.5 mg/kg. ^c Starting volume is usually adequate; increase to maximum volume (dose) only if required for pain control up to the maximum.</p> <p>To improve provider efficiency through minimizing numbers of syringes needed, starting doses have been kept at or below 10 mL and maximum doses at or below 20 mL.</p>		
<p>WARNING: Lidocaine/lignocaine with adrenaline (lidocaine/lignocaine with epinephrine) or bupivacaine with adrenaline (bupivacaine with epinephrine) should never be used for male circumcision surgery because of the risk of ischaemia (vessel constriction) of the whole penis, particularly if the penis is small. Also, the use of lidocaine/lignocaine with adrenaline (lidocaine/lignocaine with epinephrine) or bupivacaine with adrenaline (bupivacaine with epinephrine) may delay the onset of bleeding from blood vessels that require ligation or diathermy.</p>		

Source: (2)

Table 9.3. Maximum doses of lidocaine/lignocaine (2%) local anaesthetic agent

SAFE LOCAL ANAESTHETIC DOSING—STARTING ^a AND MAXIMUM ^b VOLUMES 2% LIDOCAINE/LIGNOCAINE		
Weight in kg	Starting volume	Maximum safe volume
20–29 kg ^c	2 mL	Additional 1 mL to TOTAL of 3 mL
30–39 kg ^c	3 mL	Additional 1 mL to TOTAL of 4 mL
40–50 kg	4 mL	Additional 2 mL to TOTAL of 6 mL
More than 50 kg	5 mL	Additional 2 mL to TOTAL of 7 mL

^a Starting dose of lidocaine/lignocaine is 2 mg/kg.
^b Maximum safe dose of lidocaine/lignocaine is 3 mg/kg.
^c Use 5 mL syringe so that volumes can be measured accurately.
Starting volume is usually adequate; increase to *maximum* volume (dose) only if required for pain control up to the *maximum*.

WARNING: Lidocaine/lignocaine with adrenaline (lidocaine/lignocaine with epinephrine) or bupivacaine with adrenaline (bupivacaine with epinephrine) **should never be used** for male circumcision surgery because of the risk of ischaemia (vessel constriction) of the whole penis, particularly if the penis is small. Also, the use of lidocaine/lignocaine with adrenaline (lidocaine/lignocaine with epinephrine) or bupivacaine with adrenaline (bupivacaine with epinephrine) may delay the onset of bleeding from blood vessels that require ligation or diathermy.

Source: (2)

Table 9.4. Maximum doses of lidocaine/lignocaine (2%) and bupivacaine (0.5%) local anaesthetic agents

SAFE LOCAL ANAESTHETIC DOSING—STARTING ^a AND MAXIMUM ^b VOLUMES MIXTURE OF 2% LIDOCAINE/LIGNOCAINE AND 0.5% BUPIVACAINE 1:1 MIXTURE (EQUAL VOLUMES OF EACH)		
Weight in kg	Starting volume (1:1 mixture)	Maximum safe volume (1:1 mixture)
20–29 kg ^c	1 mL of each (2 mL total)	Additional 1 mL of each drug to TOTAL of 4 mL (maximum 2 mL of each)
30–39 kg ^c	2 mL of each (4 mL total)	Additional 1 mL of each drug to TOTAL of 6 mL (maximum 3 mL of each)
40–50 kg	3 mL of each (6 mL total)	Additional 1 mL of each drug to TOTAL of 8 mL (maximum 4 mL of each)
More than 50 kg	4 mL of each (8 mL total)	Additional 1 mL of each drug to TOTAL of 10 mL (maximum 5 mL of each)

^a Starting doses of lidocaine/lignocaine are: lidocaine/lignocaine 1.5 mg/kg / bupivacaine 0.3 mg/kg
^b Maximum safe doses of lidocaine/lignocaine is 2 mg/kg and bupivacaine is 0.5 mg/kg.
^c Use 5 mL or smaller syringe so that volumes can be measured accurately.
Starting volume is usually adequate; increase up to *maximum* volume (dose) only if required for pain control up to the *maximum*.

WARNING: Lidocaine/lignocaine with adrenaline (lidocaine/lignocaine with epinephrine) or bupivacaine with adrenaline (bupivacaine with epinephrine) **should never be used** for male circumcision surgery because of the risk of ischaemia (vessel constriction) of the whole penis, particularly if the penis is small. Also, the use of lidocaine/lignocaine with adrenaline (lidocaine/lignocaine with epinephrine) or bupivacaine with adrenaline (bupivacaine with epinephrine) may delay the onset of bleeding from blood vessels that require ligation or diathermy.

Source: (2)

9.4.2. Safe injection of local anaesthetic agents

The provider doing the procedure has the responsibility to personally check the vial of anaesthesia, ensure that the correct agent at the correct concentration has been selected and check the expiry date. It is important to verify that the anaesthesia is clear—has no visible particles in it (which may suggest that the vial is contaminated)—and does not contain epinephrine (adrenaline). **Always** check the vial.

Once the needle is in place in the base of the penis, the provider should aspirate the syringe to make sure that no blood has entered the syringe. If blood enters the syringe, do not inject the anaesthetic agent(s); move the needle to a new location and aspirate again. This ensures that the anaesthetic agent(s) is not injected into a blood vessel, corpora cavernosa or corpus spongiosum. **Repeat aspiration each time the needle is moved and before any additional anaesthetic agent(s) is injected.**

Another method for injecting local anaesthetic is to fully insert the needle, aspirate to ensure that the needle is not in a blood vessel and then inject as the needle is withdrawn. With this method, it is important to inject only while the needle is being withdrawn. If the needle stops moving, then the injection must stop. Before resuming the injection, repeat aspiration to ensure that the needle is not in a blood vessel.

9.4.3. Additional analgesia

Best practice is to give the client oral analgesia (for example, 500 mg tablet of paracetamol) 30 minutes before the procedure so that the oral agent is absorbed and effective as the anaesthesia wears off. Another dose of oral analgesia can be given for the client to take before he goes home.

9.4.4. Local anaesthetic techniques

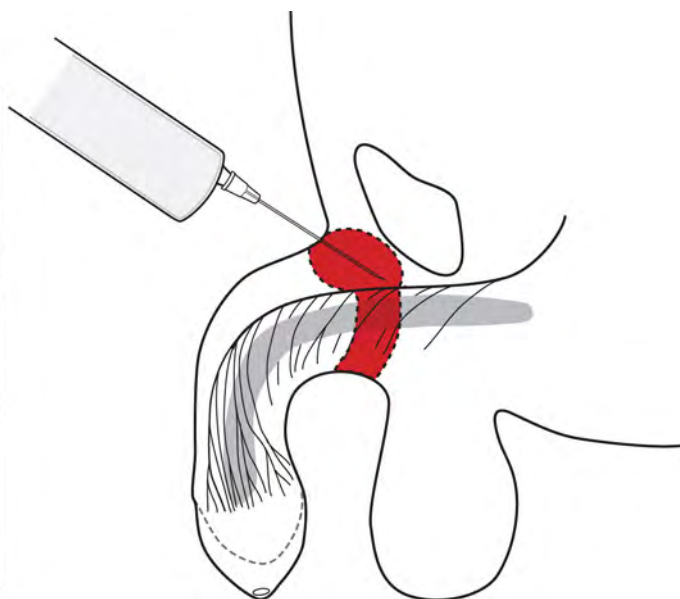
9.4.4.1. Subcutaneous ring block technique

The subcutaneous ring block technique involves administering local anaesthesia around the base of the shaft of the penis, thereby creating a subcutaneous ring of anaesthetic agent (see Fig. 9.3). This technique helps prevent any injury to the underlying penile tissue while achieving adequate control of pain on the skin of the shaft.

- Using a fine-gauge needle (23–27 gauge), first inject approximately 0.1 mL of anaesthetic agent(s) subcutaneously at 12:00 o'clock.
- Next, without withdrawing the needle, advance the needle into the subdermal space, making sure that the needle is freely mobile. At this point, aspirate the syringe and, if there is no blood, inject 2–3 mL of anaesthetic agent(s) to block the dorsal penile nerves.
- Then, advance the needle subcutaneously around each side of the penis, aspirate the syringe and, if there is no blood, inject small additional amounts of anaesthetic agent(s) to complete a half-ring of anaesthesia around the dorsal half of the shaft (see Section 9.4.4.2).
- To complete the block, make additional punctures at the 03:00 o'clock and 09:00 o'clock positions to continue the ring of anaesthesia around the ventral half of the shaft. If a puncture is made at the 06:00 o'clock position, there is a risk of urethral injury and injecting into a vessel.

Once the anaesthesia has been injected, **wait for a minimum of five minutes** (timed by a clock) before beginning the male circumcision. A common mistake is to start the procedure before the anaesthesia has had time to work. Test sensation before starting the procedure by gently pinching the foreskin with an artery forceps. If there is any residual sensation, wait for an additional two to three minutes and test again. If there is still sensation, give more local anaesthesia, taking care not to exceed the maximum safe dose (see Tables 9.1–9.4).

Fig. 9.3. The ring of local anaesthetic agent(s) after injections have been made during the ring block technique^a

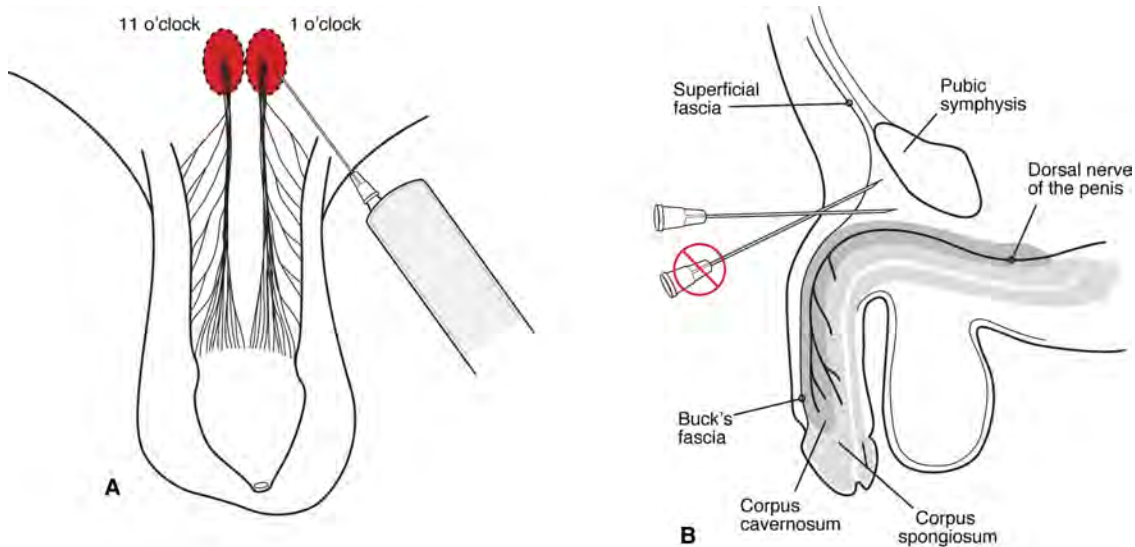


^a Photograph © R. Bailey, Kisumu Project

9.4.4.2. The dorsal nerve block

In this technique, the anaesthetic agent(s) is deposited close to the dorsal nerve (see Fig. 9.4). This gives quick and safe pain control. A fine-gauge needle (21–27 gauge) should be used.

- STEP 1.** Give two injections at the 11:00 o'clock and 01:00 o'clock positions on the dorsum of the penis in the subpubic angle.
- STEP 2.** Direct the needle at a 45° angle to the shaft. This improves the success rate of the block and reduces the risk of injury to the underlying penile structures.
- STEP 3.** Advance the needle in each of these positions (11:00 o'clock and 01:00 o'clock) to a depth of about 3 cm so that the anaesthesia is adjacent to the nerve before it branches.
- STEP 4.** Aspirate the syringe to ensure that the needle is not in a blood vessel.
- STEP 5.** Deposit the anaesthetic agent(s) close to the dorsal nerve of the penis.
- STEP 6.** Wait five minutes after giving the injection—timed by the clock—for the anaesthesia to take effect. A common mistake is to start the procedure before the anaesthesia has had time to work.

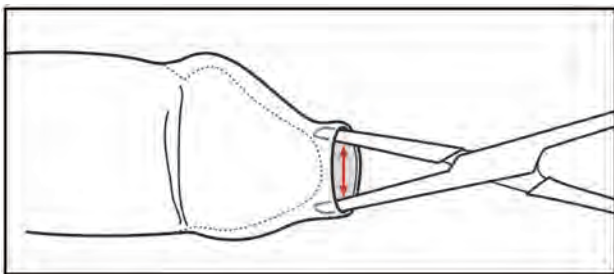
Fig. 9.4. Injection of local anaesthesia for the dorsal nerve block^a

^a (A) Injections are made at the 11:00 o'clock and 01:00 o'clock positions. (B) The needle is angled to inject under the symphysis pubis.

9.5. PREPARING THE PENIS FOR SURGERY

9.5.1. Retraction of the foreskin and managing adhesions

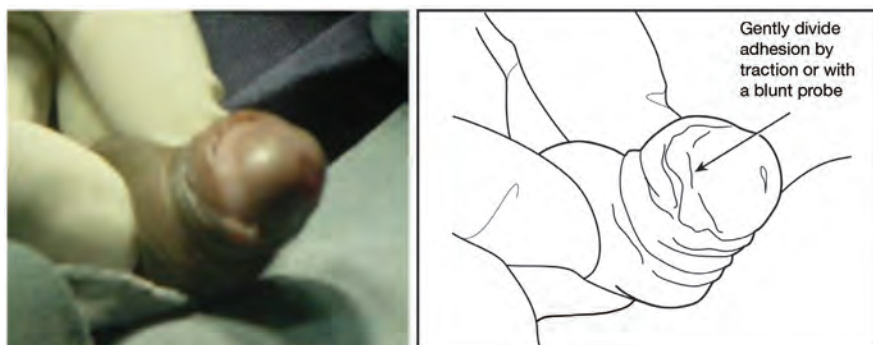Retracting the foreskin is a step that is common to all methods of male circumcision described in this *Manual*. After effective local anaesthesia has been achieved, fully retract the foreskin. If the opening (or aperture) of the foreskin is tight, it may be necessary to dilate it with a pair of artery forceps (see Fig. 9.5), but this is not usually necessary in adults and older adolescents. Take care to **just stretch the opening of the foreskin** and not to push in the forceps too far. Pushing in the forceps too far increases the risk that the tip of the forceps enters the urethral meatus and causes injury to the urethra and glans. If the dilatation causes minor tears in the skin near the tip of the foreskin, this is not a problem, as the foreskin is going to be removed; however, tears in the urethral meatus can be the start of a lifelong problem because subsequent scarring can cause urethral stricture and urinary obstruction.

Fig. 9.5. Dilatation of the aperture of the foreskin^a

^a Note: Tips of the forceps are positioned within the aperture of the foreskin, and care has been taken not to allow the tip of the forceps to accidentally enter the urethral meatus.

In younger adolescents, adhesions are common; they are nearly always physiological and not pathological. Adhesions can usually be separated easily by applying gentle pressure on them using a moist gauze swab or a blunt probe (see Fig. 9.6). If the adhesions are hard or if trying to separate them causes bleeding, then they are more likely to be pathological than physiological. The provider may decide to abandon the procedure and refer the client to an experienced surgeon or specialist. Hard scar tissue adhesions with phimosis, which prevent retraction of the foreskin and chronic balanitis, are more likely to be seen in older men but can occur (rarely) in children following balanitis in infancy.

Fig. 9.6. Retracting the foreskin to fully expose the glans, corona and coronal sulcus, and to separate any adhesion^a



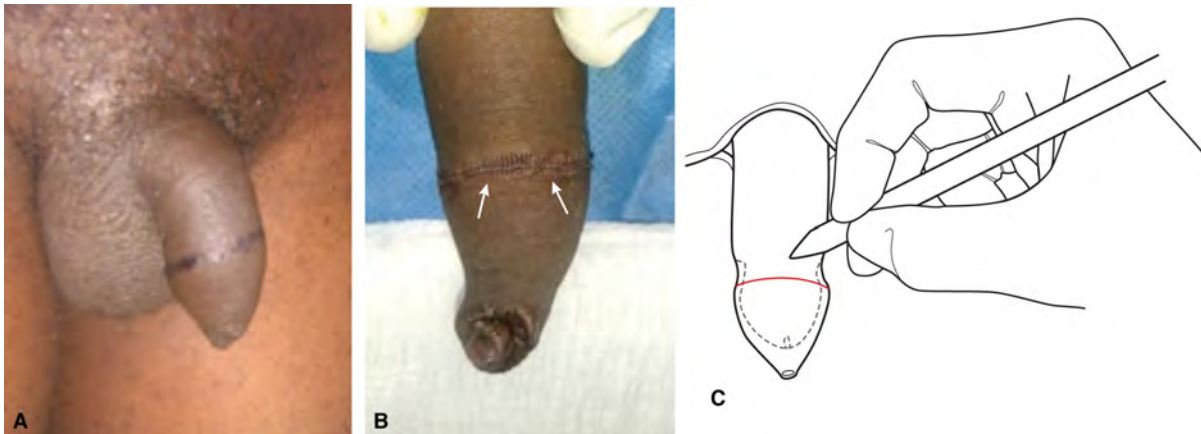
^a Photograph © R. Bailey, Kisumu Project

9.5.2. Marking the line of the male circumcision

Marking the line of the male circumcision is another step common to all conventional or device-based surgical methods described in this *Manual*; however, the placement of the line depends on the circumcision technique used. It is important to mark the line of male circumcision to avoid excess or insufficient skin removal. With the foreskin in a natural resting position, indicate the intended line of the incision with pinch marks or a marker pen for the surgical technique that will be used. Surgical marker pens are available in bright blue, and this colour shows well when the skin is deeply pigmented.

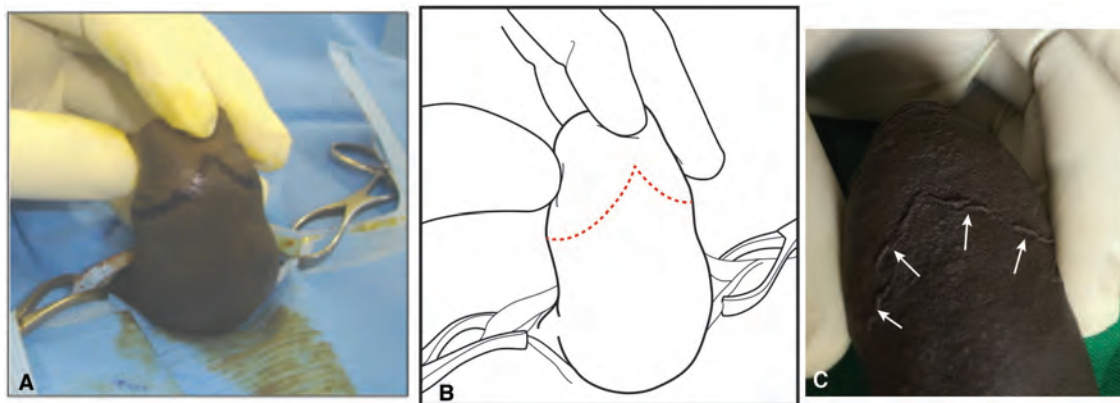
With the foreskin in the resting position and not under any traction, mark the line just distal to the prominence of the corona (see Fig. 9.7). If the line is marked too far proximally, an excessive amount of foreskin may be removed, making the placement of sutures difficult. For the sleeve resection and dorsal slit procedures, make a V-shaped mark on the ventral side (frenular side), with the point of the V towards the glans (see Fig. 9.8). For the sleeve resection method, also mark a second line of incision.

If a marker pen is not available, dabs of gentian violet may be applied with a blunt probe, the tip of an artery forceps or another sterile instrument. A further alternative is to make pinch marks with toothed forceps, but this method is slightly more traumatic; if this type of marking is used, make the incision just proximal to the pinch marks, so the tissue damaged by the pinch marks is excised with the foreskin.

Fig. 9.7. Marking the male circumcision line^{a,b}

^a (A and C) The mark is made just distal (further towards the tip of the penis) to the prominence of the coronal ridge. (B) If a marking pen is not available, small pinch marks can be made with forceps.

^b Photographs © Kasonde Bowa, Adrian Musiige and Whyson Mkandawire

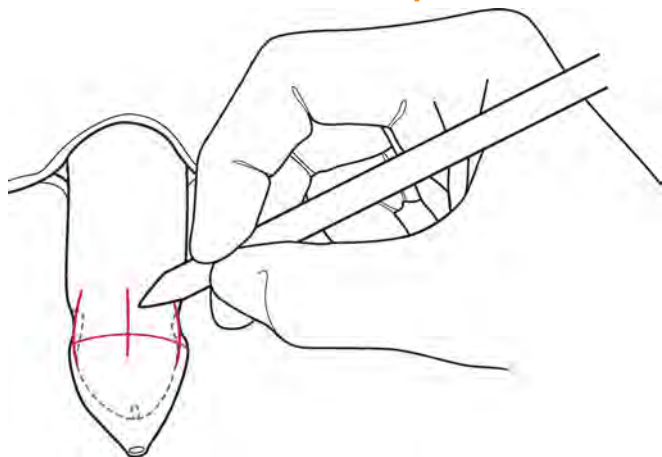
Fig. 9.8. Marking the V-shaped line^a

^a When marking before the sleeve and dorsal slit procedures, mark a V-shaped line with the apex of the V pointing towards the glans and frenulum. This V-shaped mark is not needed for the forceps-guided method, because the forceps guide the line of the incision.

9.5.3. Making realignment markings

After the removal of the foreskin and haemostasis, it will be important to ensure that the skin of the shaft can be realigned to its original position and that there is no torsion of the shaft skin in relation to the glans. Alignment can usually be achieved by lining up the frenulum and urethral meatus with the line of the midline raphe on the shaft of the penis (see Fig. 9.15). However, the raphe is commonly not in the midline; therefore, after cleaning, draping and giving local anaesthesia—but before making any incision—check the position of the midline raphe. If the raphe is not in the midline, or is difficult to see, then, in addition to marking the line of the male circumcision, make additional orientation marks (see Fig. 9.9) at the 12:00, 03:00, 06:00 and 09:00 o'clock positions so that the skin can be accurately realigned when the sutures are placed. Providers who are less experienced in doing circumcisions may find alignment markers helpful for achieving proper alignment, regardless of the position of the raphe.

Fig. 9.9. Additional skin orientation markings at the 03:00, 09:00 and 12:00 o'clock positions (shown), and 06:00 o'clock position (not shown), to help with alignment during suturing^a



^a Make additional skin orientation marks if the midline raphe is off-centre or difficult to see. These additional skin orientation markings also help if the provider is less experienced.

9.6. METHODS OF MALE CIRCUMCISION

Table 9.5 shows the advantages and disadvantages of four conventional or device-based surgical methods of male circumcision. All methods produce good results in the hands of a competent provider.

Devices can potentially reduce the time required to do a circumcision procedure and require no suturing. Another major advantage of some devices is that there is no need for local anaesthetic injection. However, there is a need for a surgical backup if device-specific complications occur. Limited information about devices is provided in Annex 9.1. (See also the manufacturer's instructions for use for each device.)

Table 9.5. Comparison of conventional and device-based surgical circumcision methods: advantages and disadvantages

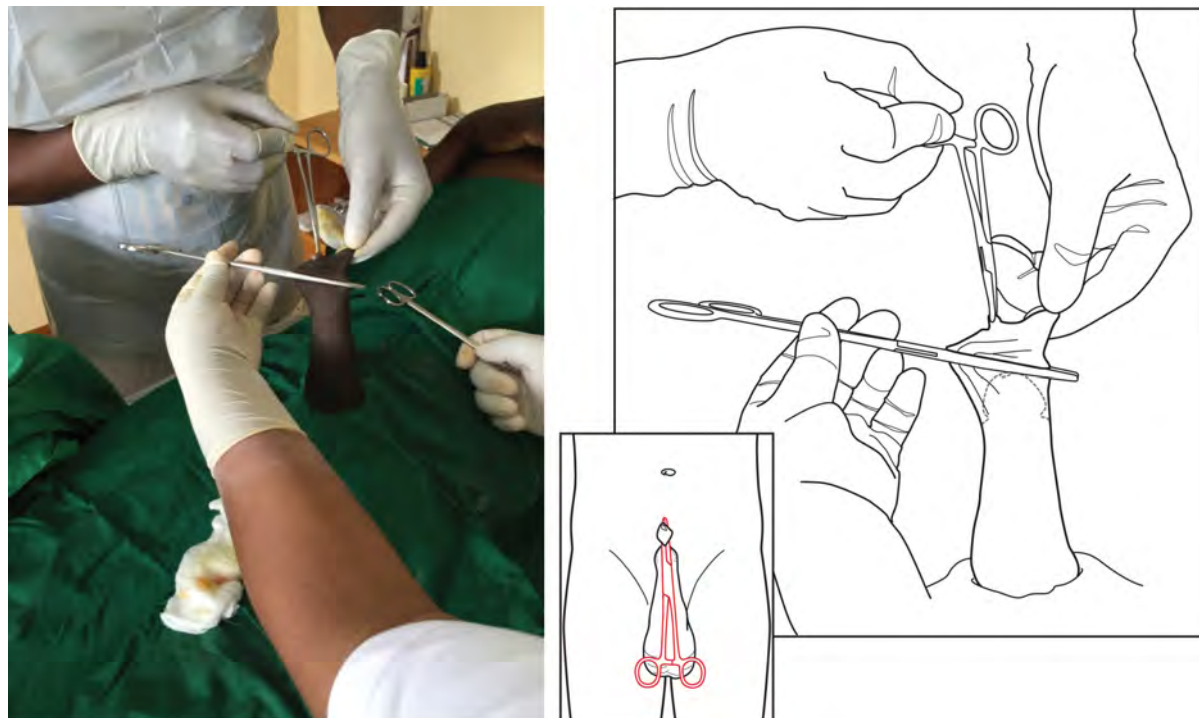
METHOD	ADVANTAGES	DISADVANTAGES
Forceps-guided	<ul style="list-style-type: none"> • Quick to learn • Faster than other methods of conventional surgery 	<ul style="list-style-type: none"> • Leaves a wider (approximately 1.5 cm) cuff of mucosal skin proximal to the corona • Glans not visualized during surgery • Should not be used in adolescent boys under 15 years of age or any male who has adhesions—or any male whose tip of the glans cannot be clearly identified by palpating the foreskin—because of difficulty identifying the glans and the risk of glans amputation
Dorsal slit	<ul style="list-style-type: none"> • Used for medical reasons, such as phimosis • Glans visualized during surgery 	<ul style="list-style-type: none"> • Slower to do and longer to teach than forceps-guided • Small risk of urethral meatus injury
Sleeve resection	<ul style="list-style-type: none"> • Excellent cosmetic outcome • Minimizes risk of removing too much or too little skin because incisions on external and inner (mucosal) layers of the foreskin are marked • Can be almost bloodless • Glans well visualized 	<ul style="list-style-type: none"> • Slower and more technical than other methods • Longer to teach
Some devices that are worn for one week	<ul style="list-style-type: none"> • Simple and quick to apply compared with surgical methods • Easier for a less-skilled provider • Reduced risk of bleeding compared with surgical methods • No stitches • Some applied with topical anaesthetic agent(s) 	<ul style="list-style-type: none"> • Need to be worn for one week • Completion of procedure requires a second visit • Brief sharp pain common at time of removal • Necrosis if foreskin retained for one week while the device is in place <ul style="list-style-type: none"> • Necrosis of the foreskin may cause an unpleasant odour and an increase in anaerobes, which increases the risk of infection, including tetanus in clients who are insufficiently vaccinated. Vaccination is required. • Need clinics or facilities to manage device-specific complications <ul style="list-style-type: none"> • For example, for some devices, there is a need for immediate, onsite surgical backup if the device slips off during application. If a device displaces in the days after the application, there is a need for surgical backup within six to 12 hours.

9.6.1. Forceps-guided method of male circumcision

The forceps-guided method **should not be used** in adolescent boys under the age of 15 years or in any male who has adhesions—or in any male whose tip of the glans cannot be clearly identified by palpating the foreskin—because of difficulty identifying the glans and the risk of glans amputation.

- STEP 1.** Prepare skin, drape skin and administer anaesthetic agent(s), as described earlier in this chapter.
- STEP 2.** Retract the foreskin and separate any adhesions, as described earlier in this chapter.
- STEP 3.** Mark the line of the incision and skin orientation marks, as described earlier in this chapter.
- STEP 4.** Grasp the foreskin at the 03:00 o'clock and 09:00 o'clock or 06:00 o'clock and 12:00 o'clock positions with two artery forceps. Place these forceps on the natural apex of the foreskin to help ensure that there is equal tension on the inside and outside surfaces of the foreskin. If this is not done correctly, there is a risk of leaving too much of the inner (mucosal) layer of the foreskin or removing too much skin on the shaft (see Fig. 9.20).
- STEP 5.** Put sufficient tension on the foreskin to pull the skin mark so that it is just distal to the glans. Taking care not to catch the glans, apply a long, straight forceps across the foreskin just proximal to the mark, with the long axis of the forceps going from the 12:00 o'clock to the 06:00 o'clock position. Before completely locking the forceps (see Fig. 9.10), feel the glans to check that it has not been accidentally caught in the forceps; then, lock it until the click sound is heard. If there is any doubt about whether the glans has been caught in the forceps, do not proceed with the forceps-guided method.

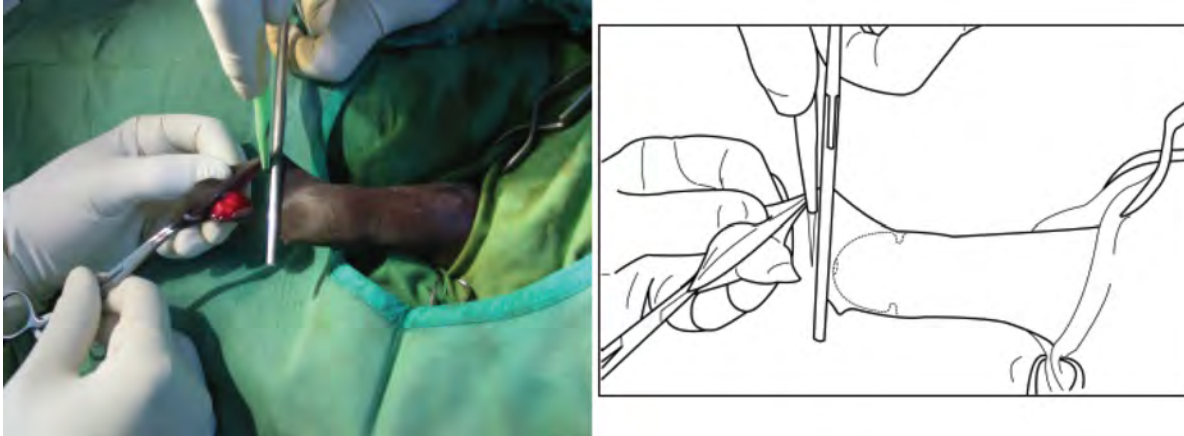
Fig. 9.10. Placing the forceps to guide the male circumcision^a



^a Take care not to catch the glans in the forceps. The forceps is slightly angled so that the line of the forceps is parallel to the line of the coronal sulcus. Place the forceps in the 06:00 o'clock to 12:00 o'clock orientation (inset).

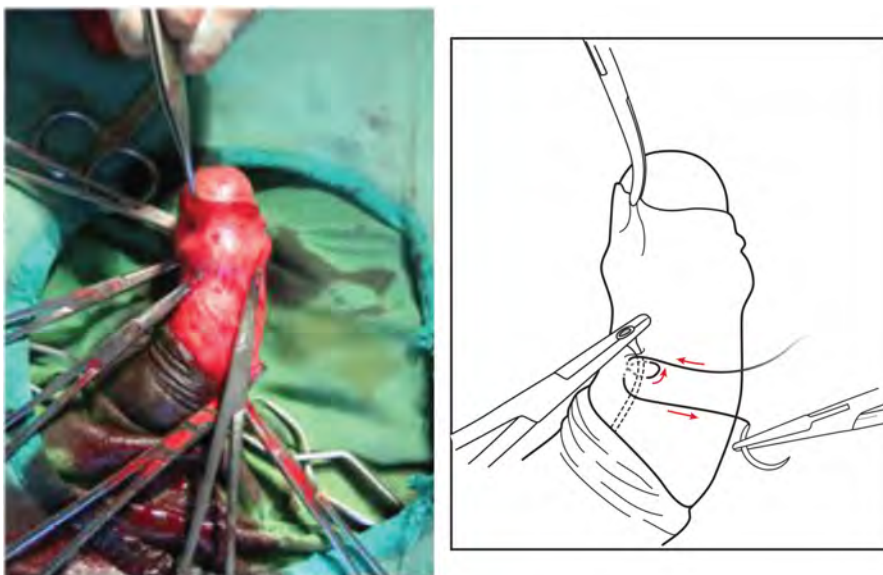
STEP 6. Using a scalpel, cut away the foreskin flush with the distal side of the forceps (the side of the forceps towards the outside or tip of the foreskin) (see Fig. 9.11). **Cutting in one smooth, decisive motion is safer and leads to better cosmetic outcomes.** The forceps protects the glans from injury; nevertheless, particular care is needed at this stage.

Fig. 9.11. Forceps-guided method: cutting off the foreskin



STEP 7. Pull back the skin to expose the raw area. Using a dry gauze swab, compress the area for two to three minutes. Clip any bleeding vessels with artery forceps. Take care to catch the blood vessels as accurately as possible and to not grab large amounts of tissue. Larger blood vessels should be underrun with a suture and ligated. Take care not to place haemostatic stitches too deeply (see Fig. 9.12). Diathermy, if it is available, may be used for smaller blood vessels.

Fig. 9.12. Applying artery forceps to blood vessels to stop bleeding, and using a suture to underrun the blood vessel



STEP 8. (Optional, extra step) The forceps-guided method leaves a broader cuff of mucosal skin than other surgical methods, and many providers trim this to leave a narrower cuff. **If this additional step is done, do not trim too close to the coronal sulcus. Leave approximately 0.5–0.6 cm of cuff, so sutures can be safely placed (see Fig. 9.13).** Also, **do not trim close to the base of the frenulum, as this makes it difficult to control bleeding from the frenular artery (see Box 9.3).**

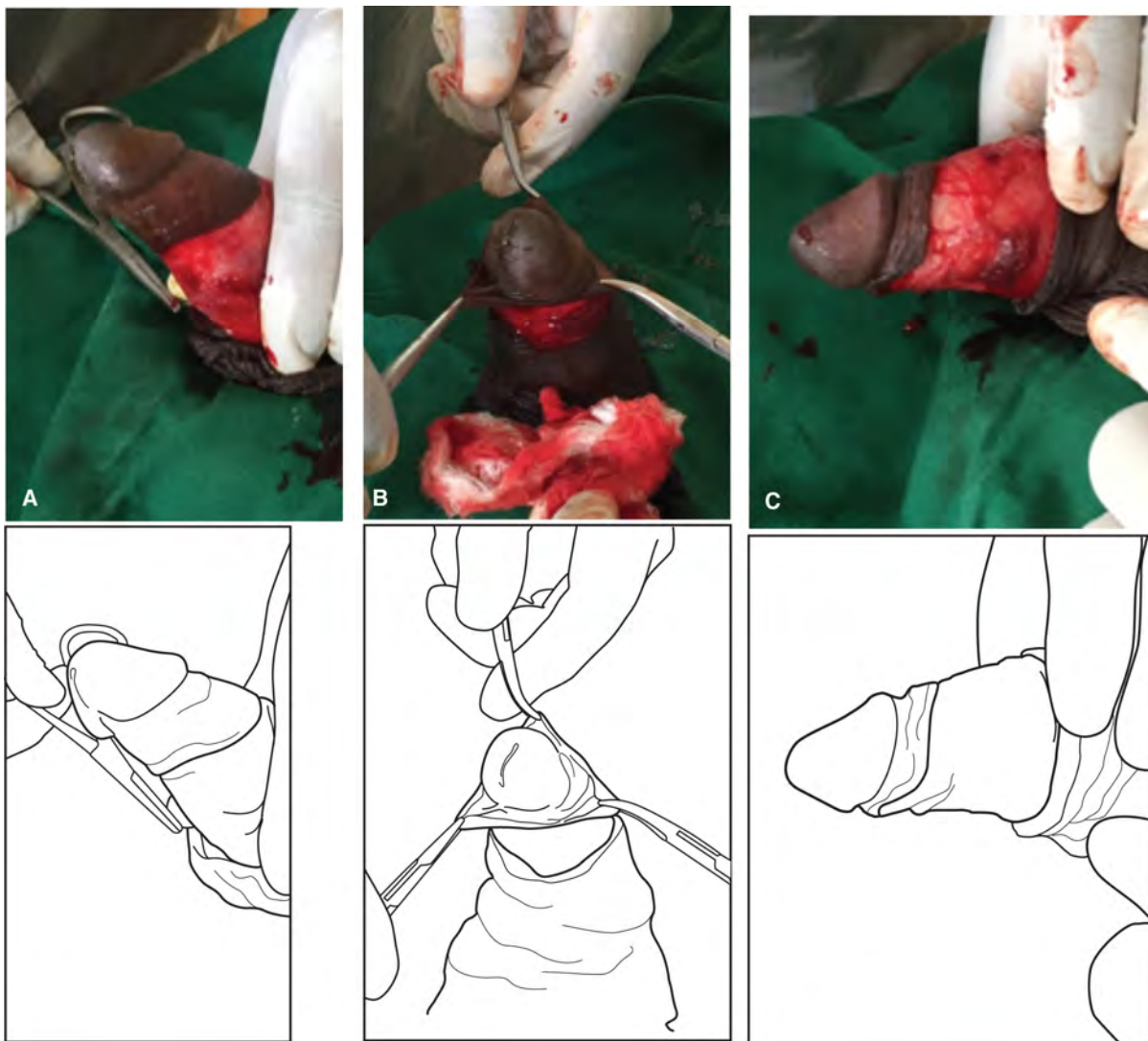
Box 9.3. Management of bleeding in the frenular area

When managing bleeding in the frenular area or on the ventral side of the penis, take great care when stopping the bleeding from the frenular artery so as not to injure the urethra. Damage to the urethra may cause tissue breakdown and a hole between the urethra and the skin surface (urethral fistula). If this occurs, it can be very difficult to treat. The following precautions should be taken:

- Avoid the use of diathermy, as this can burn into the underlying urethral wall and cause tissue necrosis.
- If there is bleeding from the frenular area, control bleeding with pressure using a gauze swab. Then, accurately locate the bleeding vessel, accurately apply artery forceps and ligate or transfix the vessel. If transfixion is used, take care to avoid using thick suture material, including big chunks of tissue in the suture and passing the suture into deeper layers. This is important because the urethra is near the skin's surface in the area immediately under the frenulum. If a suture passes too deeply, then it may enter the urethral wall and cause damage, which may result in tissue breakdown and a urethral fistula.

Normally, the horizontal mattress frenular suture (see Step 9) stops minor bleeding. Again, when placing this suture, do not include deep layers and accidentally catch the urethral wall.

Fig. 9.13. Optional, extra step in forceps-guided method^{a,b}



^a (A) Appearance of the inner layer (mucosal layer) cuff after removal of the foreskin; (B) application of a curved forceps to stabilize the cuff prior to trimming with scissors; (C) the cuff after trimming with scissors.

^b Photographs © Augustino Hellar

STEP 9. Place a horizontal mattress suture at the frenulum (see Fig. 9.14). When placing the frenulum suture, take care not to take too deep a bite because the urethra is just underneath the base of the frenulum (see Box 9.3; see Chapter 7, Fig. 7.2). Also, take care to align the midline skin raphe with the line of the frenulum (see Fig. 9.15). For clients with an off-centre raphe, see Box 9.4.

Fig. 9.14. Horizontal mattress suture at the frenulum (06:00 o'clock position)

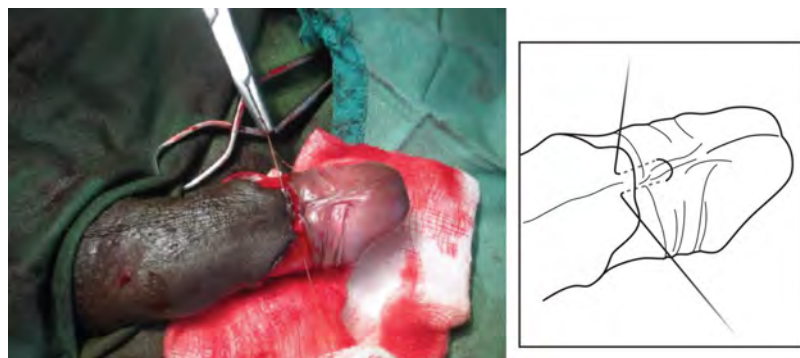
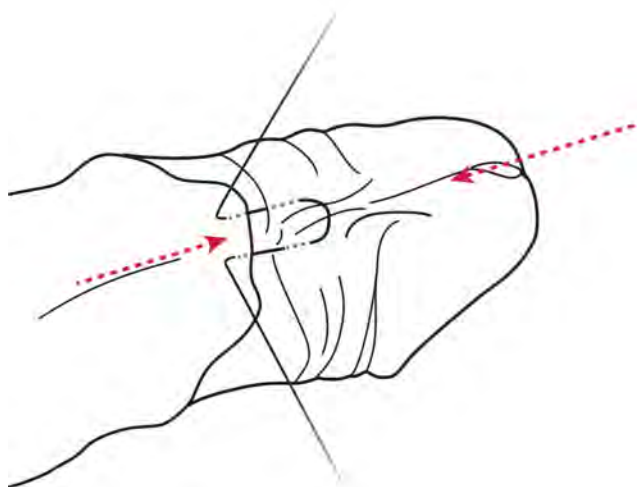


Fig. 9.15. Arrows showing the alignment of the midline skin raphe on the shaft of the penis with the line of the frenulum^a



^a The urethra is close to the surface in the 06:00 o'clock position, and this suture must not be placed too deeply.

Box 9.4. A good frenulum stitch

- Do not take too deep a bite because the urethra is just below the base of the frenulum.
- Take care to properly align the frenulum and the midline: misaligning the frenulum and the midline can result in misalignment of the whole male circumcision closure.
- Avoid tightening the suture. If the suture is too tight, it can cause an area of ulceration or necrosis at the frenulum.
- Avoid injuring the urethra. Always remember that the urethra is very close to the skin surface at the frenulum. Do not stitch too deeply, and avoid injuring the urethra.

STEP 10. Place a vertical mattress suture opposite the frenulum, in the 12:00 o'clock position (see Fig. 9.16). Place the suture so that there is an equal amount of skin on each side of the penis, between the 12:00 o'clock and 06:00 o'clock positions. (The technique of vertical mattress suture is shown in Chapter 8, Fig. 8.9.) Place two further vertical mattress stitches in the 03:00 o'clock and 09:00 o'clock positions (see Chapter 8, Fig. 8.11).

On the horizontal mattress suture, it is helpful to leave a long end at the frenulum (at the 06:00 o'clock position). On the vertical mattress suture, it is helpful to leave a long end in the opposite side (at the 12:00 o'clock position). The long ends of the sutures can be held by an assistant using artery forceps to stabilize the penis during suturing (see Fig. 9.17). There is no need to leave a long end of suture for the vertical mattress sutures placed at the 03:00 o'clock and 09:00 o'clock positions. These long ends are cut short at the end of the procedure once all the other skin stitches are in place.

Fig. 9.16. Placing a vertical mattress suture at the 12:00 o'clock position

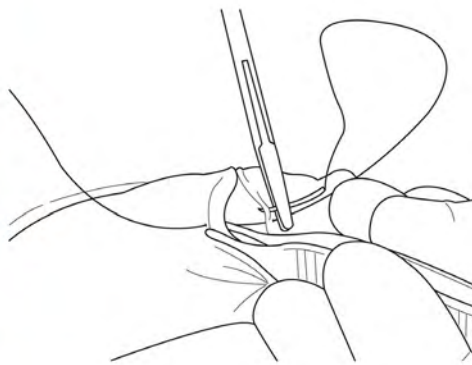
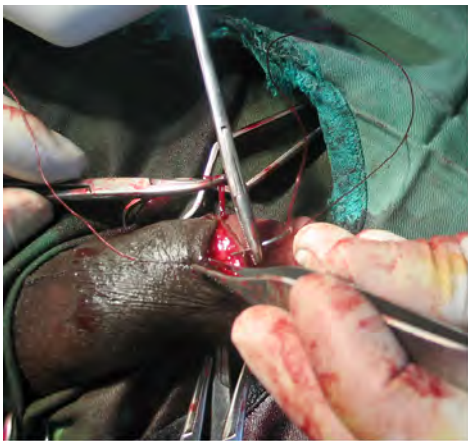
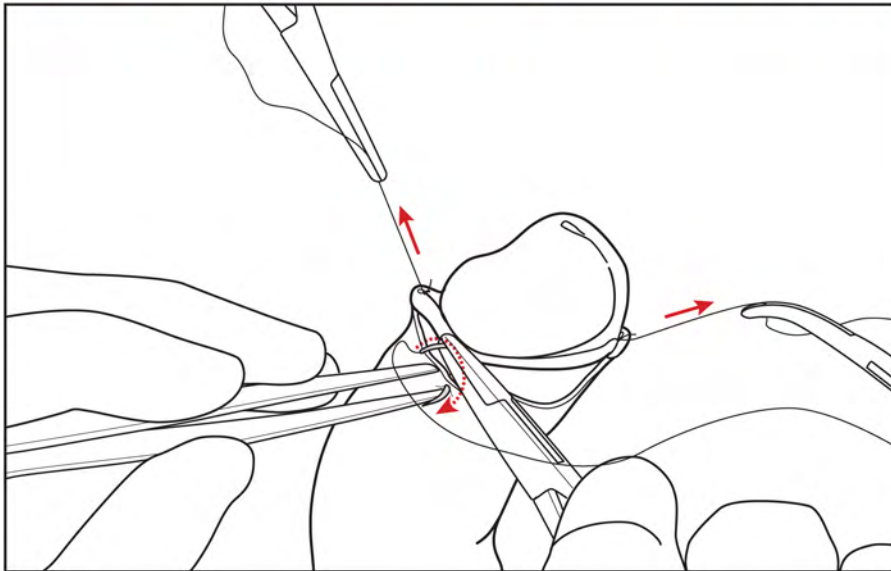
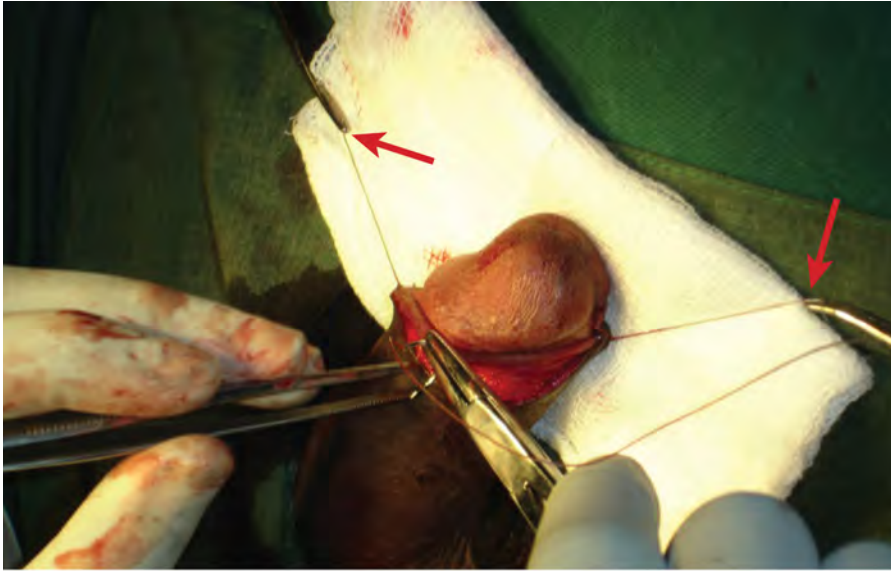


Fig. 9.17. Stabilizing the penis during suturing^a

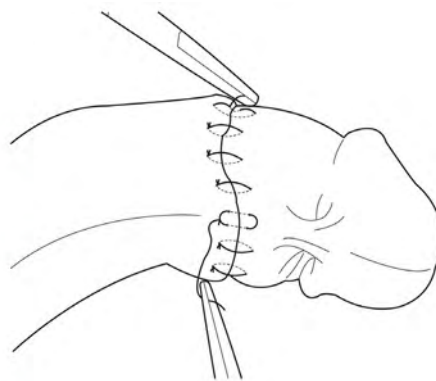
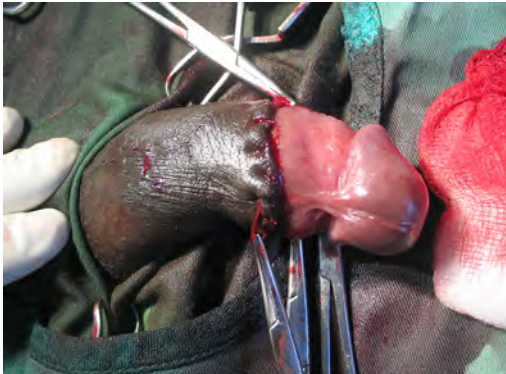


^a The penis is stabilized by an assistant holding two artery forceps (see arrows) attached to the long end of the sutures at the 06:00 o'clock and 12:00 o'clock positions.

STEP 11. After placing sutures at the 06:00, 12:00, 03:00 and 09:00 o'clock positions (principal sutures), place two or three simple sutures in the gaps between them (see Fig. 9.18). (The technique of simple interrupted sutures is shown in Chapter 8, Fig 8.8.)

Depending on the skin pigmentation, there may be a strong contrast between the colour of the penile shaft skin and the remaining mucosa (see Fig. 9.18). With time, the exposed mucosal skin will become darker and the contrast less marked.

Fig. 9.18. Placement of simple sutures between the mattress sutures^a



^a Two or three simple sutures are placed between the principal mattress sutures (which are at the 12:00, 03:00, 06:00 and 09:00 o'clock positions).

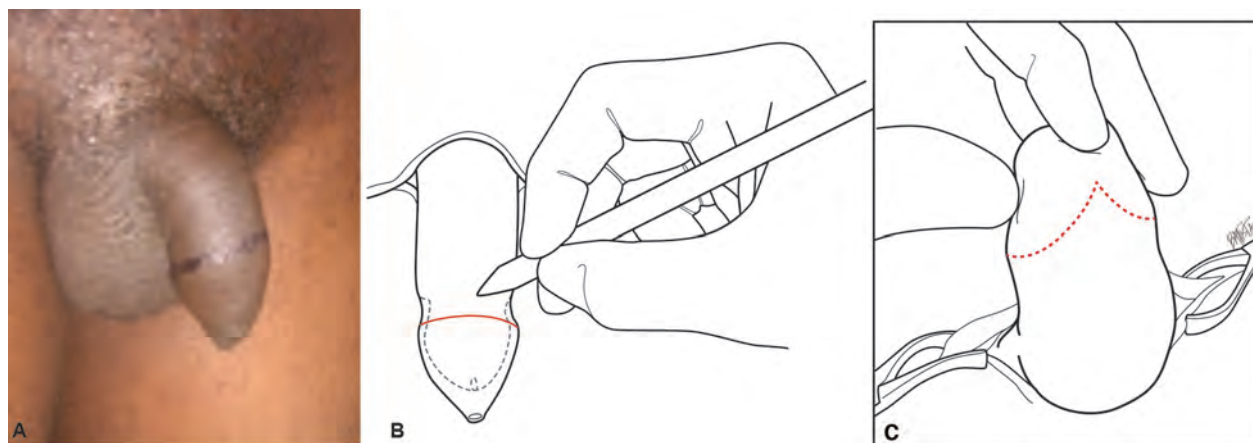
STEP 12. Once the procedure is finished, check for bleeding. If there is bleeding and care has been taken with shaft haemostasis, then the bleeding is likely to be from the skin edges. Sometimes, it is necessary to place an extra simple skin stitch, but bleeding from the skin edges typically stops within a short period of time after pressure has been applied to it with a gauze swab. If bleeding seems to be coming from deeper in the wound, then remove a few or all of the skin stitches and reinspect the penis shaft to locate the source(s) of the bleeding. **There is often pressure to finish a procedure quickly, but time spent on stopping the bleeding is valuable. It is always better to make sure bleeding has stopped than to take a risk.** Once bleeding has stopped, apply a dressing to the wound (see Section 9.7).

9.6.2. Dorsal slit method of male circumcision

STEP 1. Prepare skin, drape the skin and administer anaesthesia, as described earlier in this chapter.

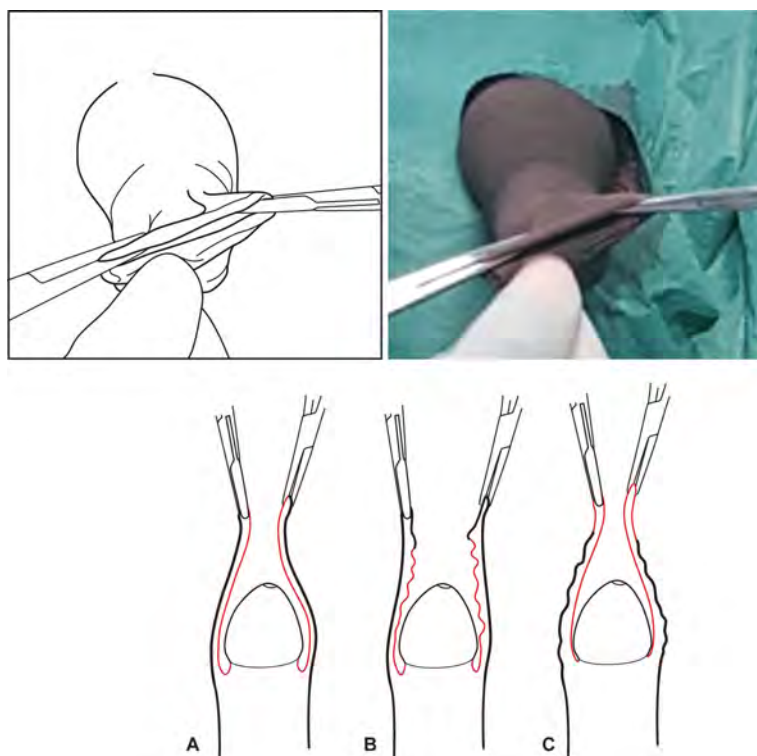
STEP 2. Retract the foreskin and remove any adhesions, as described earlier in this chapter.

STEP 3. Mark the intended line of incision (see Fig. 9.19). Make the skin mark just distal to the prominence of the corona (further towards the tip of the penis). The mark should have a V shape on the ventral side (frenular side), with the point of the V towards the glans. Note the line of the ventral midline raphe, and if there is any deviation from the midline, make additional orientation marks at the 03:00, 12:00 and 09:00 o'clock positions.

Fig. 9.19. Marking the incision line for the dorsal slit procedure^a

^a Photograph © Kasonde Bowa

STEP 4. Apply artery forceps at the 03:00 o'clock and 09:00 o'clock positions, to the apex of the foreskin meatus. Take care to apply the artery forceps to the foreskin so that there is equal tension on the inner and outer aspects of the foreskin (see Fig. 9.20). The purpose of this step is to ensure that there is correct tension on the inner and outer parts of the foreskin.

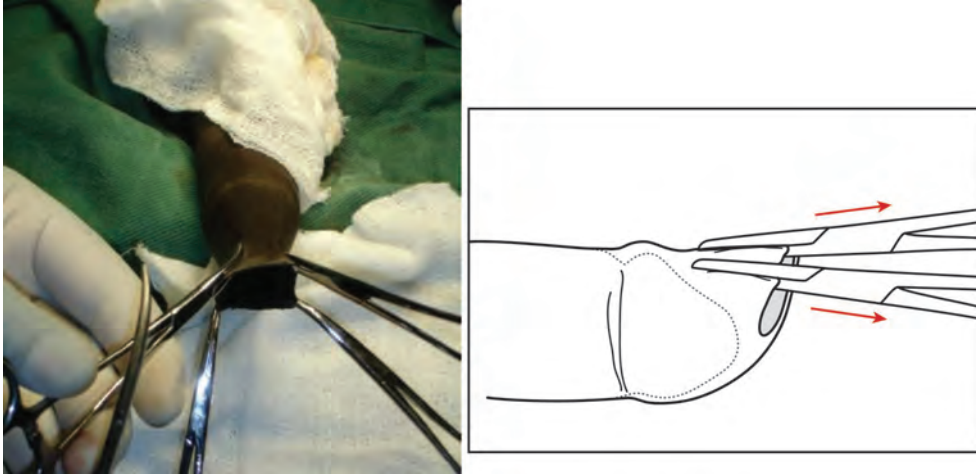
Fig. 9.20. Applying forceps to the foreskin^{a,b}

^a Apply the forceps to the tip of the foreskin with equal tension on the outer skin and the inner (mucosal) skin. (A) Forceps correctly applied to tip of foreskin; (B) forceps incorrectly applied, taking too much outer skin; and (C) forceps incorrectly applied, taking too much inner (mucosal) skin.

^b Photograph © Dr. Josephine Otchere-Darko

STEP 5. Keeping tension on the previously applied 03:00 o'clock and 09:00 o'clock forceps, place two artery forceps on the foreskin at the 11:00 o'clock and 01:00 o'clock positions (see Fig. 9.21) by taking 1–2 cm of foreskin between the forceps' blades (Fig. 9.21). Check that the inside blades of the two artery forceps are lying between the glans and foreskin, and the blades have not been inadvertently passed up the urethral meatus.

Fig. 9.21. Placing artery forceps at the 11:00 o'clock and 01:00 o'clock positions^{a,b}

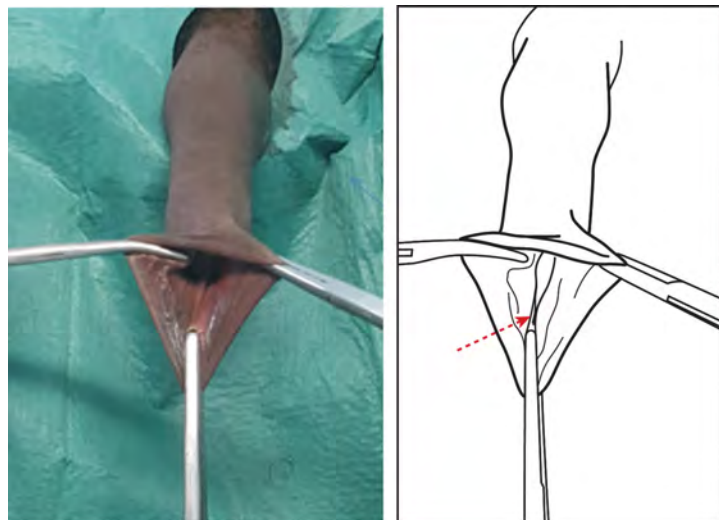


^a The drawing shows forceps applied at the 11:00 o'clock and 01:00 o'clock positions. In the photo, forceps at the 11:00 o'clock and 01:00 o'clock positions are held apart to display the area where the dorsal slit is going to be made (between these forceps). Note the 03:00 o'clock and 09:00 o'clock tensioning forceps are not shown in the drawing.

^b Photograph © Dr. Josephine Otchere-Darko

STEP 6. Keeping the 11:00, 01:00, 03:00 and 09:00 o'clock forceps in position, apply forceps at the 6:00 o'clock position, so as to take a 1 cm bite of foreskin (typically); however, exactly how much bite to take depends on the length of the foreskin. The tip of the inside blade of the forceps at the 06:00 o'clock position should nearly reach the fold of the frenulum, and the tip of the outside blade of the forceps should nearly reach the apex of the marked V on the marked line of incision. It is important that the 06:00 o'clock forceps be placed accurately and not too far in because the cut to remove the foreskin should be made between the inner layer of the foreskin and the frenulum—NOT between the base of the frenulum and the shaft of the penis. Provided the 06:00 o'clock forceps is placed correctly, the cut will be in the right place. If the cut is made too close to the base of the frenulum, then there is increased risk of bleeding from the frenular artery, which is difficult to control, thereby leading to the risk of urethral damage during attempts to control this bleeding. Once the 06:00 o'clock forceps is in position, the 03:00 o'clock and 09:00 o'clock tensioning forceps can be removed, thereby leaving three forceps in position—11:00, 01:00 and 06:00 o'clock (see Fig. 9.22).

Fig. 9.22. Forceps at the 06:00 o'clock position, with the inner blade nearly reaching the fold of the frenulum (see arrow)^{a,b}

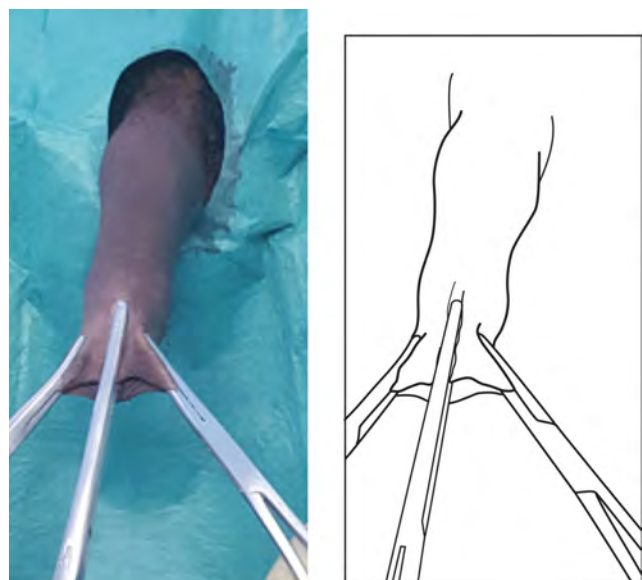


^a The forceps at 11:00 o'clock and 01:00 o'clock positions are under tension to display the interior of the foreskin meatus.

^b Photograph © Dr. Josephine Otchere-Darko

STEP 7. Between the two top artery forceps (11:00 o'clock and 01:00 o'clock), apply forceps at the 12:00 o'clock position and close it tightly to crush the line of the dorsal slit. This crushing helps to reduce bleeding when the dorsal slit is made (see Fig. 9.23).

Fig. 9.23. Applying forceps at 12:00 o'clock position to crush the foreskin before making the dorsal slit^{a,b}

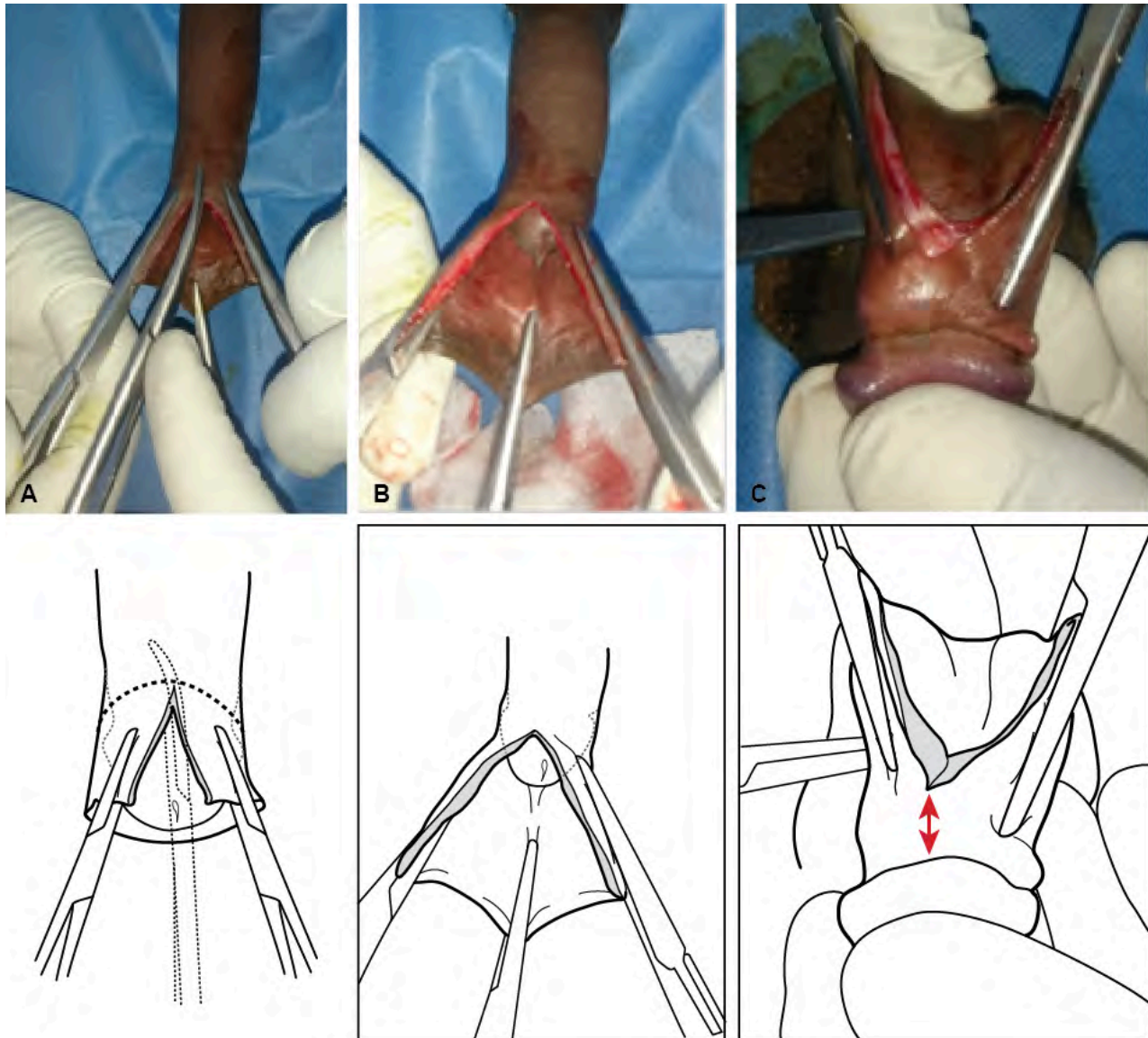


^a Note that the forceps at the 06:00 o'clock position is not shown.

^b Photograph © Dr. Josephine Otchere-Darko

STEP 8. Remove the 12:00 o'clock crushing forceps and, using dissection scissors, make a cut along the middle of the crushed foreskin (the dorsal slit) up to the previously marked incision line (see Fig. 9.24). This is best done in two stages: 1) make part of the dorsal slit cut; 2) check inside and outside to note the position of the dorsal cut, in relation to the outer marked male circumcision line and with respect to the width of the mucosa, proximal to the coronal sulcus—and then cut further as necessary. The ideal cuff of mucosal skin left behind is **approximately 0.5–0.6 cm**. Do not cut the mucosal side too near the coronal sulcus and glans; take care to leave sufficient mucosa to take the sutures.

Fig. 9.24. Cutting the dorsal slit^{a,b}



^a (A) Cutting the dorsal slit; (B) dorsal view of completed dorsal slit; and (C) inside view showing dorsal slit reaching and leaving **approximately 0.5–0.6 cm** cuff of inner layer (mucosal).

^b Photographs © Dr. Josephine Otchere-Darko, Adrian Musiige and Whyson Mkandawire

STEP 9. Follow instructions in this step, which is a modification of the one in the 2009 edition of this *Manual*, to make the circumferential cut to remove the foreskin (see Box 9.5).

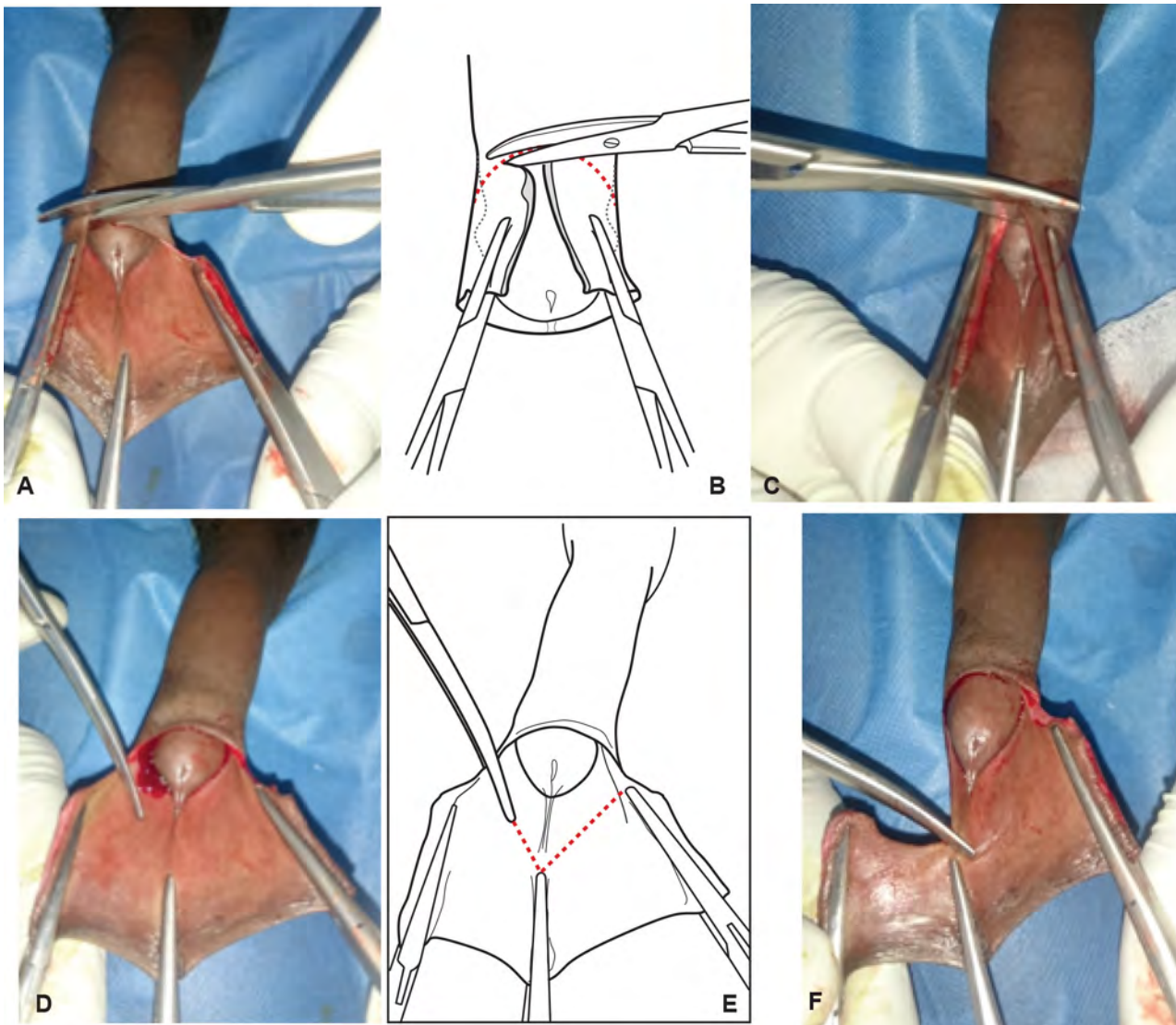
Box 9.5. Step modified from 2009 edition of this *Manual*

The dorsal slit technique described in this *Manual* is slightly modified from the technique described in the 2009 edition of this *Manual*. The modified technique is recommended because it reduces the chance that the foreskin will be cut too close to the coronal sulcus, a problem encountered with the previously described method. (In the 2009 version, the technique described a simple freehand cut without the forceps at the 06:00 o'clock position or ventral V marking.)

Starting at the 12:00 o'clock position, the circumferential cut is made using scissors, first in one direction and then the other, so just over half of the foreskin is cut free.

- Take care to follow the marked skin incision line and also to leave **approximately 0.5–0.6 cm** cuff of mucosa adjacent to the coronal sulcus.
- Once the dorsal half of the foreskin is cut free, the cut then continues towards the frenular ridge (see Fig. 9.25). The direction of the cut changes to make a V shape that corresponds to the line drawn previously, reaching the apex of the V shape at the frenular ridge and the tip of the forceps at the 06:00 o'clock position.
- Note that the foreskin is kept on traction by the assistant. Again, care must be taken to leave **approximately 0.5–0.6 cm** cuff of mucosa and to not get too close to the coronal sulcus. The change of direction at the frenular ridge at 06:00 o'clock is important as it helps to ensure that the cut is away from the base of the frenulum. If this is not done, then there is increased chance of difficulty in controlling bleeding from the frenular artery—and the risk of urethral injury when attempts are made to control bleeding.

Fig. 9.25. Cutting of the circumferential at the foreskin^{a,b}

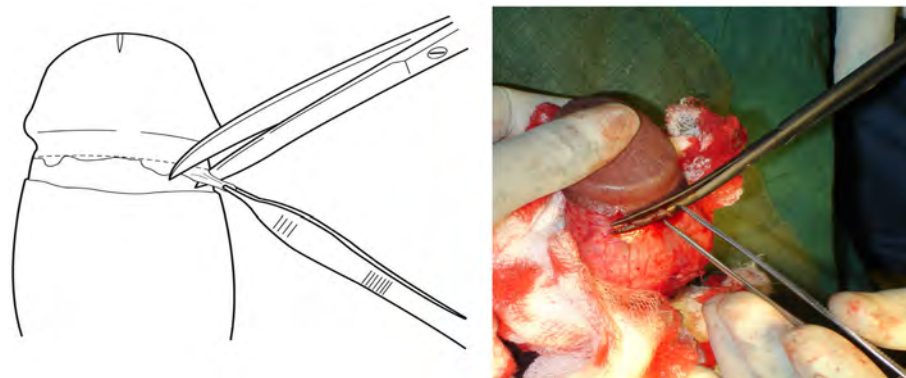


^a Starting at the 12:00 o'clock position, the circumferential cut is made using scissors, first in one direction (A, B) and then the other (C), so just over half of the foreskin is cut free. Once the dorsal half of the foreskin is cut free, the cut then continues towards the frenular ridge (D). The direction of this cut changes to make a V shape, corresponding to the red dotted lines (and the V shape of the outer skin mark [D, E]). Photograph D shows the start of the V-shaped cut. Photograph F shows the cut reaching the apex of the V shape at the frenular ridge (note that the cut is well way from the base of the frenulum, thus reducing the chance of bleeding from the frenular artery).

^b Photographs © Adrian Musiige and Whyson Mkandawire

STEP 10. If necessary, trim the mucosal edge if it is uneven. However, if care was taken to display and visualize the mucosa and outer aspects of the foreskin when making the circumcision cut, then the edge of the cut will usually be straight. If any ragged edges remain, they can be trimmed (see Fig. 9.26); however, always take care to leave **approximately 0.5–0.6 cm** of skin proximal to the corona for suturing. Also, take care to not trim or cut into the deeper tissue of the shaft of the penis, particularly in the area of the frenulum.

Fig. 9.26. Trimming the inner (mucosal) layer of the foreskin



STEP 11. Stop any bleeding, and proceed with suturing, as described in Steps 7–11 of the forceps-guided method.

STEP 12. Check again for bleeding and manage as needed, as described in Step 12 of the forceps-guided method. Once there is no bleeding, apply a dressing (see Section 9.7).

9.6.2.1 Tips for dorsal slit male circumcision

- When resecting the foreskin, keep looking at the inner foreskin to ensure that not too much skin is removed.
- Take particular care at the 06:00 o'clock frenular position.

9.6.3. Sleeve resection method of male circumcision

The sleeve resection method requires a higher level of surgical skill and takes slightly longer than other methods. If diathermy is available, the procedure can be virtually bloodless, and the cosmetic results are better than with the other two techniques. However, there is more room for surgical error either by cutting too far into deeper tissue when making the two circular incisions or by cutting too deeply when dissecting the skin flap free.

STEP 1. Prepare skin, drape the skin and administer anaesthetic agent(s), as described earlier in the chapter.

STEP 2. Retract the foreskin and remove any adhesions, as described earlier in the chapter. If the foreskin does not retract easily, it may be necessary to make a partial dorsal slit, as described earlier in the chapter (see Fig. 9.24).

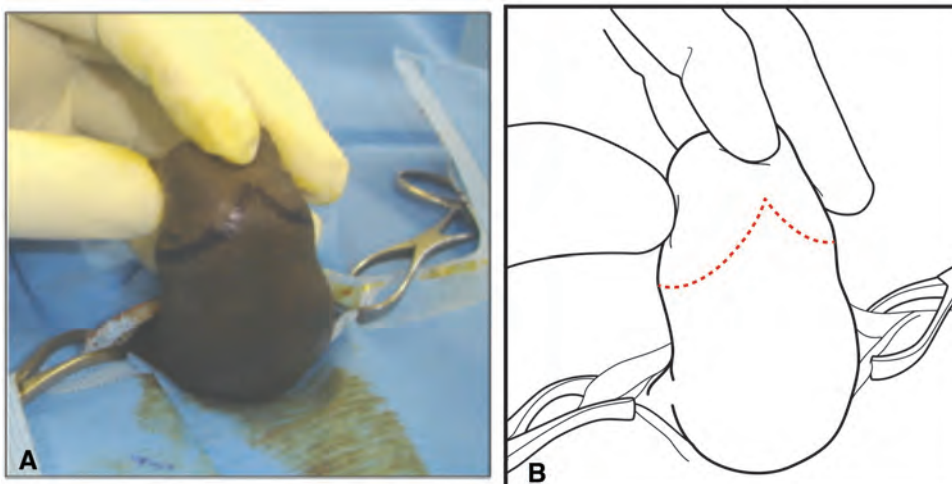
STEP 3. The sleeve resection technique is unique in that two separate lines of incision must be marked, referred to here as the outer and inner lines of incision. First, mark the intended outer line of the incision (see Fig. 9.27) and, if necessary, draw orientation marks, as described earlier in the chapter. The skin mark should be made just distal to the prominence of the corona (that is, further towards the tip of the penis). On the ventral side (frenular side), the mark should have a V shape, with the point of the V towards the glans (see Fig. 9.28).

Fig. 9.27. Marking the line of the outside cut, at or just below the corona^a



^a Photograph © R. Bailey, Kisumu Project

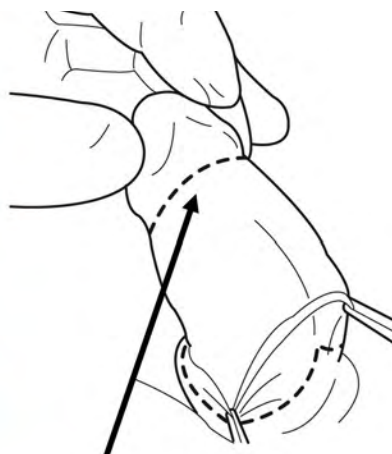
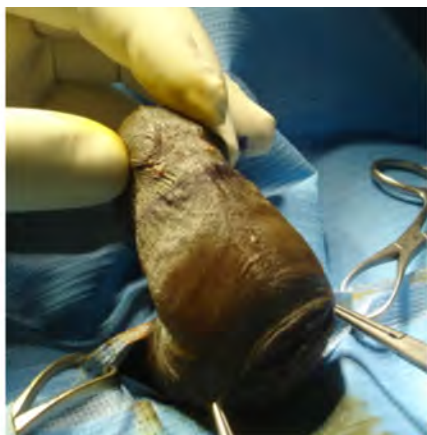
Fig. 9.28. Marking the V on the ventral side of the penis^{a,b}



^a A V-shaped mark is drawn on the ventral side (underside) of the penis; the point of the V-shaped mark is towards the frenulum. Provided the midline raphe is in the midline, the apex of the V-shaped mark should correspond with the line of midline raphe.

^b Photograph © Professor S. Watya

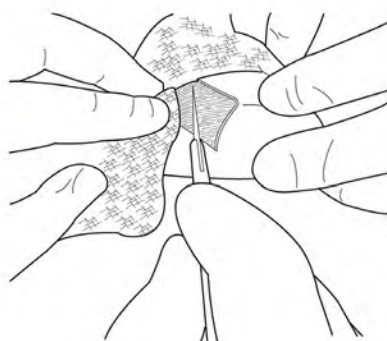
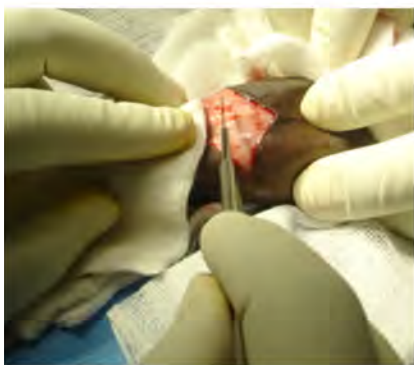STEP 4. Retract the foreskin and mark the inner (mucosal) incision line 1–1.5 cm proximal to the corona. At the frenulum, the incision line crosses horizontally (see Fig. 9.29).

Fig. 9.29. Marking the inner incision line^a

^a Photograph © Professor S. Watya

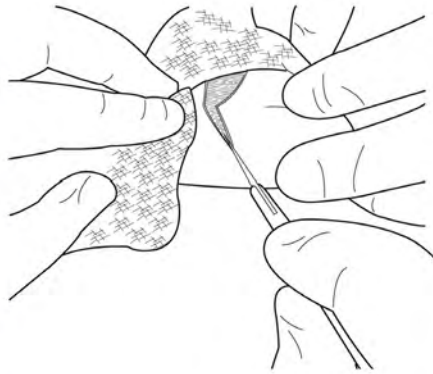
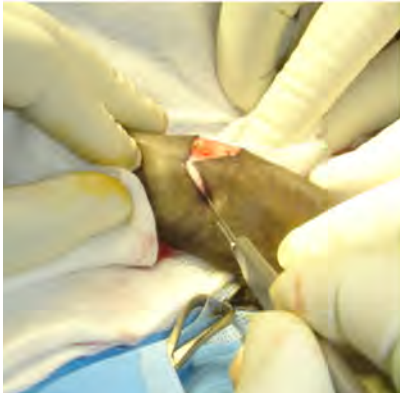
STEP 5. Using a scalpel, make incisions along the marked lines, taking care to cut through the skin to the subcutaneous tissue but not deeper (see Figs 9.30–9.32). As the incision is made, the assistant should retract the skin and keep it under tension with a moist gauze swab. Keeping proximal and distal tension to stretch the skin causes the skin to separate as soon as it is cut and lessens the risk of making too deep a cut.

An artery forceps should be applied to any vessel that is bleeding significantly; the vessel should then be tied or secured with an underrunning suture. Bleeding from small vessels can be stopped with diathermy, if available. If the cut has not been made too deeply, most bleeding will be from the edges of the skin and can be stopped by placing a simple pressure over the bleeding with a gauze swab; diathermy should not be used near the skin edge.

Fig. 9.30. Incising along the marked line^a

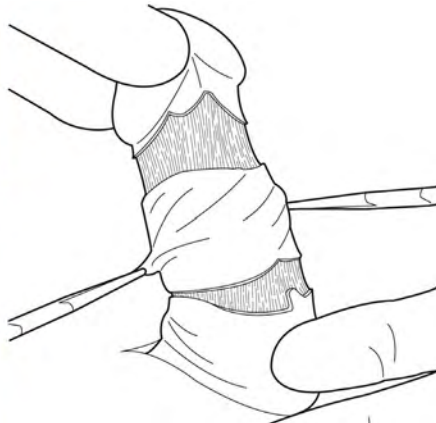
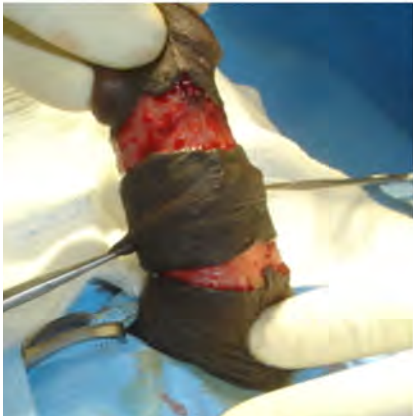^a Photograph © Professor S. Watya

Fig. 9.31. Incising the V-shaped line on the underside of the penis^a



^a Photograph © Professor S. Watya

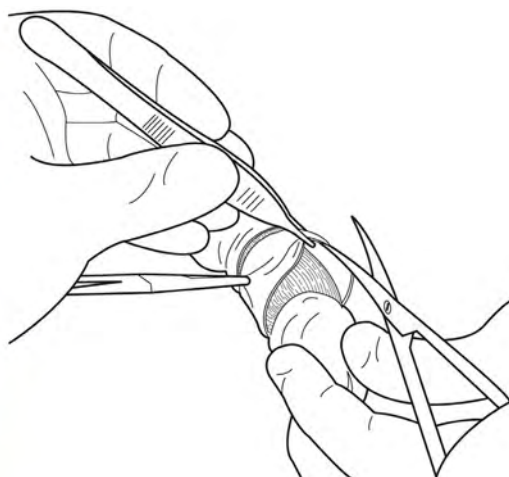
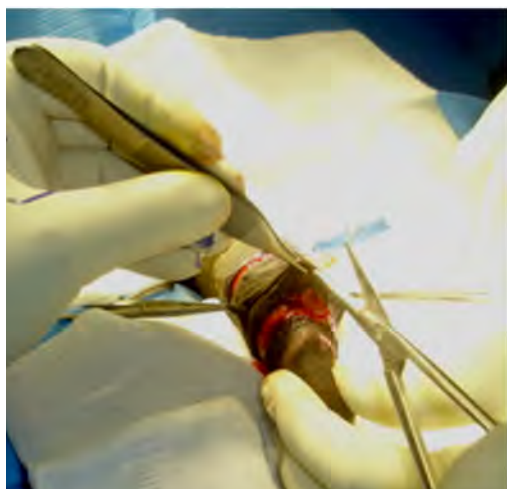Fig 9.32 Completed incisions leaving a sleeve of foreskin^a



^a Photograph © Professor S. Watya

STEP 6. Using a pair of scissors, cut the skin vertically between the proximal and distal incisions at the 12:00 o'clock position (see Fig. 9.33).

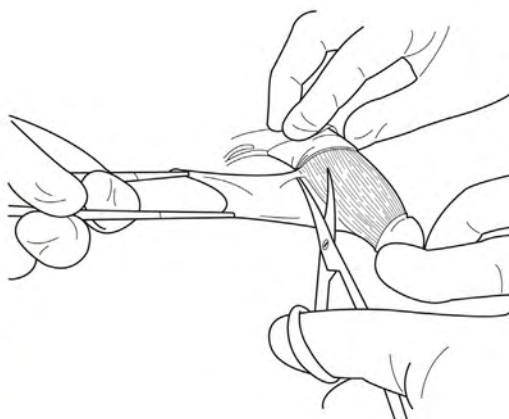
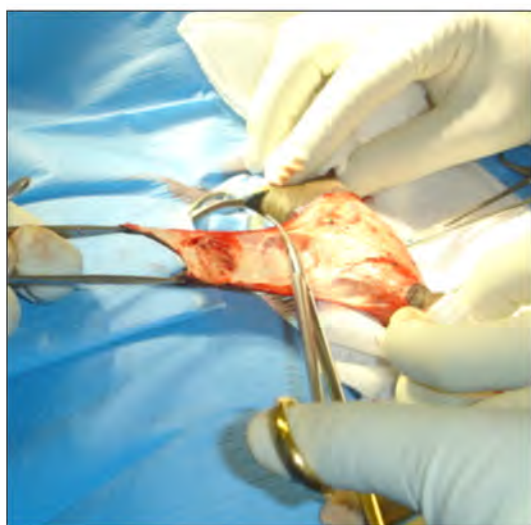
Fig. 9.33. Cutting the skin between the outer and inner incisions^a



^a Photograph © Professor S. Watya

STEP 7. Hold the sleeve of the foreskin under tension with two artery forceps and dissect the skin from the shaft of the penis using dissection scissors. The plane of dissection should be just beneath the skin and the superficial connective tissue, leaving the deeper fascia (Buck's fascia) in place (see Fig. 9.34).

Fig. 9.34. Dissecting the sleeve of skin away from the shaft of the penis^a



^a Photograph © Professor S. Watya

STEP 8. Stop any bleeding and close the skin incision with sutures, as described in Steps 7–11 of the forceps-guided method.

STEP 9. Check for bleeding again, and manage bleeding as needed, as described in Step 12 of the forceps-guided method. Once there is no bleeding, apply a dressing (see Section 9.7).

9.6.4. Variations in technique needed when there is phimosis or frenular scarring

The techniques described in this *Manual* assume that the foreskin and frenulum are normal. However, circumcision can be undertaken at the clinic level in the presence of minor abnormalities, provided that the circumcision team has sufficient experience. Any abnormalities should be detected in the preprocedure examination of the penis, which should include full retraction of the foreskin. Two abnormalities—phimosis and tight or scarred frenulum—are common indications for medical circumcision and require a slight variation in technique, as outlined below.

9.6.4.1. Phimosis

Phimosis is a narrowing of the aperture or opening of the foreskin to the extent that the foreskin cannot be retracted. The tip of the foreskin may appear white because of scar tissue. If the scar tissue is extensive, then the man is not eligible for circumcision at the clinic level and should be referred to a higher level of care.

- The first step in all circumcision procedures is to mark the foreskin with the line of incision. If the **sleeve resection method** is used, the phimosis will prevent retraction of the foreskin, meaning that the second line of incision near the corona cannot be marked. In this case, a small dorsal slit should be made, just long enough to allow the foreskin to be retracted. Once retracted, any adhesions can be separated and any debris under the foreskin can be removed with a gauze swab soaked in povidone iodine or chlorhexidine. Once all adhesions have been removed, the second line of incision on the foreskin near the corona can be marked, and the circumcision procedure can proceed as usual.
- In the **forceps-guided and dorsal slit methods**, the line of incision is marked on the outer aspect of the foreskin in the normal manner. However, with minor degrees of phimosis, it may be necessary to make a small dorsal slit to allow full retraction and cleaning under the foreskin before proceeding with the procedure. The forceps-guided method should not be used if the foreskin cannot be retracted.

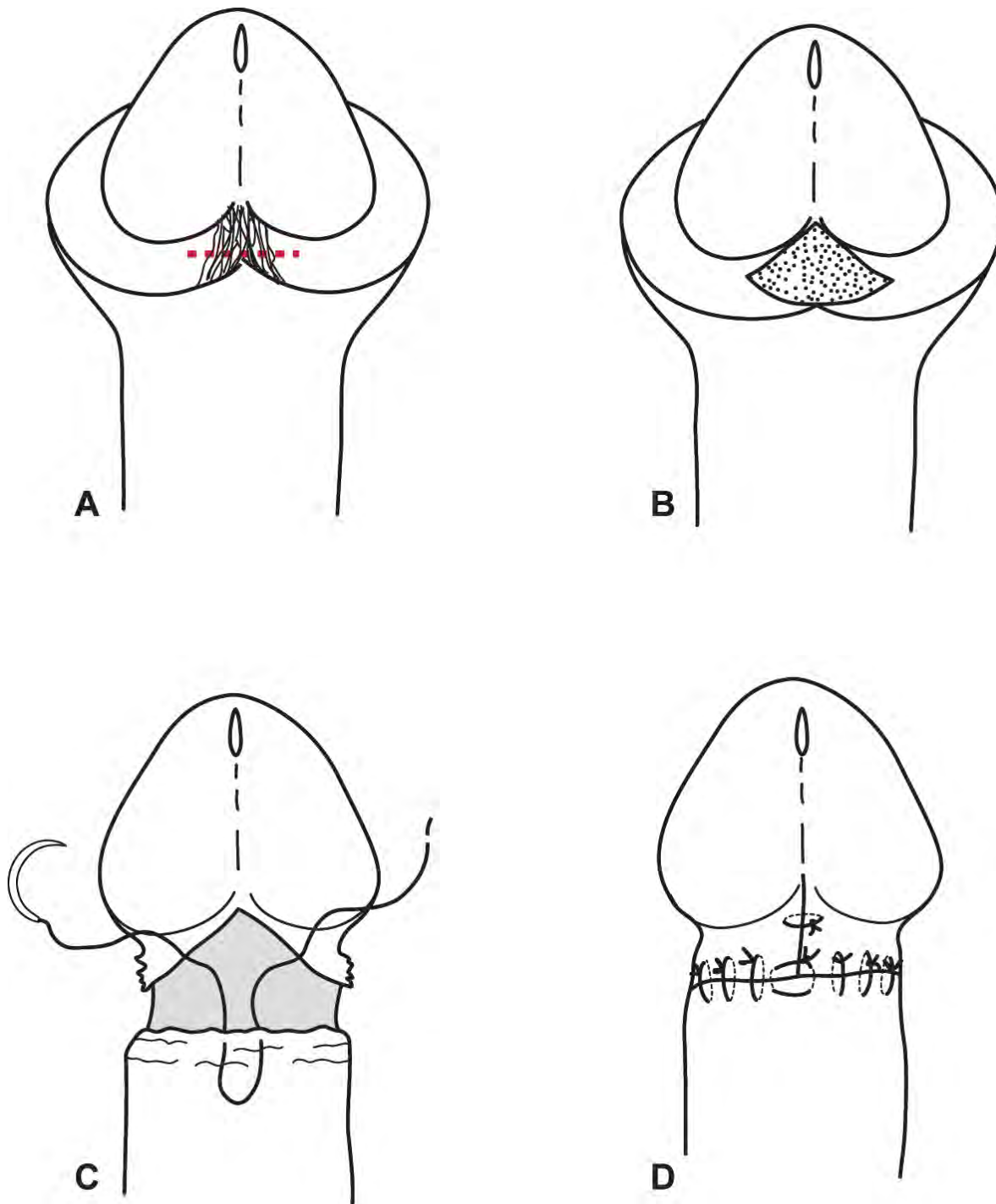
9.6.4.2. Tight or scarred frenulum

All males have a band of tissue (the frenulum) on the ventral side of the penis, just below the glans. Usually, the frenulum does not interfere with retraction of the foreskin. During early sexual experiences, the frenulum may be stretched as the foreskin is retracted, and minor tears are a frequent problem. Such tears can heal, leaving inelastic scar tissue, which tightens and makes further tearing and scarring more likely. The problem can be seen when the foreskin is retracted during physical examination. Instead of the normal colour frenulum, a tight band of white tissue is seen (see Fig. 9.35[A]). This restrictive frenular band can easily be corrected during circumcision.

To correct the restrictive frenular band, spread the foreskin open and retract it ventrally to put the band under tension. Using dissection scissors, snip the band at its centre, taking care not to injure the urethra, which is just under the frenulum. Control any bleeding from the frenular artery by careful tying or by underrunning. After the frenulum has been cut, there will be an inverted, V-shaped defect (see Fig. 9.35[B]).

The circumcision can then be performed as usual, except that the penile skin should not be sutured up to the apex of the frenular defect because this will cause increased tension on the ventral side. This tension can cause curvature of the penis or make erection or coitus uncomfortable. Instead, close the V-shaped defect by placing the frenular suture 1–2 cm (depending on age of the client and penis size) back from the apex of the V-shaped defect, taking in both sides of the defect (see Fig. 9.35[C]). The V-shaped incision is thus converted into an inverted T (see Fig. 9.35[D]). The defect overlying the frenulum is closed with one or two transverse sutures (only one shown in Fig. 9.35[D]), and the rest of the circumcision wound is closed as for a normal circumcision.

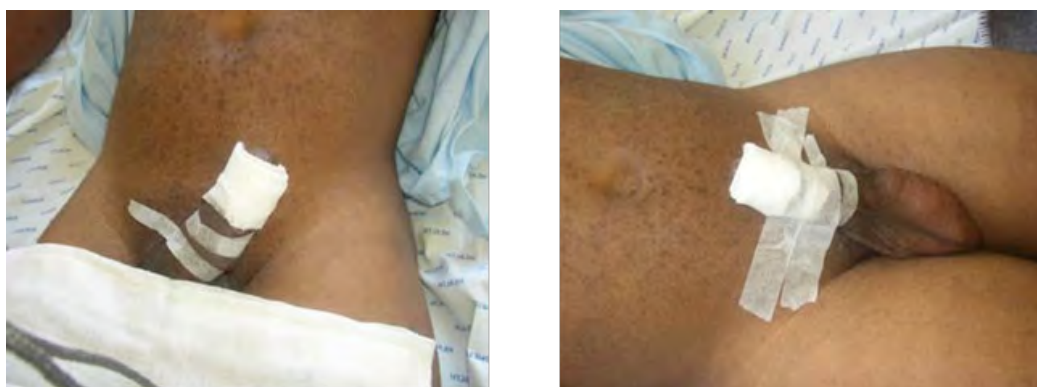Fig. 9.35. Variation in technique if the frenulum is tight or scarred



9.7. DRESSING

A standard penile dressing technique is used for the forceps-guided, dorsal slit and sleeve resection methods. Once all bleeding has stopped (as described in the final step of each surgical method used), place a piece of petroleum jelly-impregnated gauze swab around the wound. Place a dry, sterile gauze swab over the one already placed and secure both gauzes in position with adhesive tape. Strap the penis to the lower abdomen using adhesive tape or other means (for example, close-fitting underwear); this helps to minimize oedema (tissue swelling) in the first 24–48 hours postprocedure. Do not apply the dressing too tightly or too loosely. A very tight dressing will cause discomfort, difficulty in passing urine and oedema of the glans, and could potentially restrict the blood supply—causing necrosis of the glans (see Fig. 9.36).

Fig. 9.36. Standard dressing



The dressing should be left on for 24–48 hours. The use of adhesive tape has the advantage of applying mild, constant pressure while allowing the penis to stay in place. From this point, the client will undergo postprocedure assessment and counselling before going home.

Ideally, after the designated period of time has passed, the client should return to the clinic or facility where the male circumcision was done to have the dressing removed and the wound assessed for normal healing. Depending on the clinic or facility and other circumstances, arrangements may be made for him to go to another clinic or facility for postprocedure follow-up and dressing removal.

9.8. RECORDKEEPING AND REPORTING

Good documentation is a critical part of any service provision, even more so when the service provided carries any risk of harm to the client. Be sure to document service provision by using required client forms and review documentation provided by others carefully. On the day of male circumcision, record in the procedure room log the name of the client, date and type of procedure performed; do this before the client leaves. Refer to Chapter 4 for detailed guidance on recordkeeping and reporting.

9.9. TIPS

9.9.1. For safe use of local anaesthetic agent(s)

- A new needle and syringe must be used on each occasion local anaesthetic agent(s) and be withdrawn from the local anaesthetic vial.
 - Do not double-dip into a multidose vial (that is, do not insert a used needle or a used syringe attached to a new needle to re-enter the vial). If further anaesthetic agent(s) is needed, **use a new needle and new syringe**. Double-dipping with a needle or syringe that has already been used (even on the same client) will cause blood contamination in the entire vial.

- With each movement of the needle, aspirate the syringe to ensure that the needle is not in a blood vessel, the corpora cavernosa or corpus spongiosum.
- The recommended starting dose of the anaesthetic agent(s) is sufficient in most cases.

Do not exceed the weight-based maximum safe dose of local anaesthetic agent(s); maximum dose of lidocaine/lignocaine (1% or 2%) when given alone is 3 mg/kg of body weight. When lidocaine/lignocaine and bupivacaine are combined, the suggested maximum dose of lidocaine/lignocaine is 2 mg/kg of body weight, and the suggested maximum dose of bupivacaine is 0.5 mg/kg of body weight.

- Select safety-engineered syringes (also known as autodisable syringes) if possible. Various features are available, but some of these are not compatible with safe, local anaesthetic techniques. Features that prevent reuse are to be encouraged as long as they do not interfere with the provider's ability to aspirate to check for blood (to ensure that the needle is not in a blood vessel, the corpora cavernosa or corpus spongiosum) (3).

9.9.2. For safe dosage of local anaesthetic agents

- Two percent lidocaine/lignocaine is likely to give better anaesthesia than 1% lidocaine/lignocaine.
- One percent lidocaine/lignocaine is good for small clients; 2% lidocaine/lignocaine is good for large clients.
- Breakthrough pain can be controlled by an additional block at the base of the penis.

9.9.3. For achieving adequate anaesthesia during male circumcision

- The penis can be anaesthetized for male circumcision surgery using the dorsal nerve block or the subcutaneous ring block. Either technique gives good anaesthesia provided that the technique is done well.
- For skilled providers, a combination of dorsal nerve block and subcutaneous ring block achieves excellent and quicker anaesthesia. In this situation, the dorsal nerve block is done first. Care must be taken not to exceed the maximum safe anaesthetic dose.
- Before beginning the procedure, it is important for the provider doing the procedure to know the recommended starting dose and the maximum dose based on the client's weight (see Tables 9.1–9.4).
- Lidocaine/lignocaine acts quickly while bupivacaine lasts longer. A combination of both agents gives the best immediate (preprocedure) and postprocedure anaesthesia.
- Ensure that the anaesthetic needle is in the correct plane.
 - The tip of the needle should be mobile as it lies in the loose subcuticular tissue.
 - There should be no resistance to the injection of anaesthetic agent(s). If it is difficult to inject the anaesthetic agent(s), it is likely that the tip of the needle is embedded in the thick, fibrous tissue (tunica albuginea) that covers the erection chambers (corpora cavernosa).
 - The provider should always aspirate the syringe before injecting anaesthetic agent(s) to make sure the needle is not in a blood vessel.
- It is important for the provider doing the procedure to allow sufficient time for the anaesthetic agent(s) to work.
- Before beginning the procedure, it is important for the provider doing the procedure to ensure that the client's penis is anaesthetized by testing the client's sensation to pain.

9.9.4. For forceps-guided male circumcision

- Forceps-guided method should not be used in adolescent boys under 15 years of age or in any male who has adhesions—or in any male whose tip of the glans cannot be clearly identified by palpating the foreskin—because of difficulty identifying the glans and the risk of glans amputation.

- With forceps-guided male circumcision, try to avoid trimming the inner mucosa. If it is necessary to trim the inner mucosa, use a pair of scissors—do not use anything else.
- Before closing the forceps to flatten the foreskin, use fingers to massage the glans away from the clamp line and to ensure that the glans is also free of the arterial clamp. There have been a number of instances of glans injury (laceration or partial amputation) in younger adolescents.

9.9.5. For wound dressing

- Use a clean, simple dressing.
- Avoid making the dressing too tight.
- Elevate the penile shaft with tight underwear or strapping (for example, an adhesive tape).
- Counsel the client to keep the dressing on for 24–48 hours.

KEY MESSAGES

This chapter gives step-by-step instructions for performing a circumcision on an adult or an adolescent male. It covers tissue handling, skin preparation, local anaesthesia, the circumcision itself, suturing and dressing of the wound. Three conventional surgical methods are described: forceps-guided, dorsal slit and sleeve resection. Mechanical action of male circumcision devices is also described, as well as the reference to information on devices that have been recommended and prequalified by the World Health Organization for use in public health programmes (see Annex 9.1).

- Surgical male circumcision should be done using local anaesthesia and using the dorsal nerve block or the subcutaneous ring block, or both.
- The dorsal slit method can be used for any age, but the forceps-guided should not be used in adolescent boys under 15 years of age or in any male who has adhesions—or in any male whose tip of the glans cannot be clearly identified—because of difficulty identifying the glans and the risk of glans amputation.
- The marking of the incision site is vital to ensure that the correct amount of foreskin is removed (not too much and not too little).
- Gentle and accurate tissue handling reduces tissue trauma and the consequences of trauma, which are infection, delayed healing and scarring.
- Good haemostasis using vessel ligation, transfixion sutures or accurate diathermy reduces postprocedure adverse events.
- To achieve a good cosmetic outcome, suture the wound carefully. Do not use too many sutures, and ensure that there is correct tension (not too tight or too loose) while suturing.

ANNEX 9.1. DEVICES FOR MALE CIRCUMCISION

Devices can be described according to their mechanism of action and circumstances when they are used (1). Devices that are in situ (remain in place) are applied to the foreskin; part or all of the device is in situ and is removed at a second visit some days after application (usually seven days).

Surgical assist devices are used to achieve male circumcision surgery in place of some or all of the standard surgical instruments; at the end of the procedure, no part of these assist devices remains in contact with the client's body (2, 4).

A9.1.1. In situ devices

In situ devices work by compressing the foreskin between two surfaces, thereby stopping bleeding and allowing the foreskin to be removed at the time of device placement or after necrosis of the foreskin has occurred (at about one week).

There are two main types of in situ devices for adults: clamp devices and elastic collar compression devices. Clamp devices include the subcategories of collar clamp and vice clamp. The mechanism of action for both clamps consists of rapid, tight compression between hard surfaces to achieve haemostasis. Compression is sufficient to prevent slippage of tissue from the device, such that the foreskin can be removed at the time of or soon after device application. Part of the device or the entire device is left in situ for more than 24 hours (usually one week). Good anaesthesia is required because the sudden tight compression is painful. This pain suppression is achieved by an injection of a local anaesthetic. However, new data are becoming available on the use of topical anaesthetic agent(s) and placement of the device after waiting 20–40 minutes for the topical anaesthesia to take effect.

With elastic collar compression devices, the mechanism of action consists of slow compression between an elastic ring and a hard surface. Compression is sufficient to occlude circulation and produce tissue ischaemia. Part or all of the device and the foreskin are left in place for more than 24 hours (usually one week), thereby causing ischaemic necrosis of the foreskin. At the time of this *Manual's* publication, the foreskin should not be removed at the time of application of the device because the safety is not yet demonstrated (to prevent slippage and bleeding without the foreskin remaining). Such devices can be applied with a topical anaesthetic agent(s) and without the need for an injected local anaesthetic agent(s).

Advantages of using device-based surgical circumcision compared with conventional surgical methods:

- shorter procedure time
- less provider skill needed
- limited bleeding
- lower risk of glans or urethral injury compared with surgical methods
- provides a guide for the circumcision, reducing the chance of too much or too little skin removal
- easy to train providers on using the device
- good final cosmetic result

Disadvantages of using device circumcision:

- Client must wear the device for one week. This may interfere with work and other activities.
- Second visit is needed to remove the device and, depending on the device type, the necrotic foreskin.
- During screening or even in the procedure room, some clients are found to be ineligible for device circumcision. For these clients, either circumcision should be provided using surgical methods on the same day or the circumcision should be deferred to another day. Clients whose procedure is deferred need to come back on another occasion to the same or a different clinic or facility for surgical circumcision.

- Surgical backup is needed to deal with device-related adverse events, and providers need to be familiar with the management of device-related adverse events, for example, the gross penile swelling that may occur if device displacement happens 24–48 hours after placement of the elastic collar compression clamp.
- Elastic collar compression devices, where the foreskin remains in place for one week, may cause an unpleasant odour (because of the necrosing foreskin) and an increase in anaerobic growth in the space between the prepuce and glans; the anaerobes may increase the risk of infection, including tetanus, in clients who are insufficiently vaccinated. Clients must be adequately vaccinated prior to the method.
- Because the device has to be worn for one week and healing only starts after device removal, healing requires about one more week.
- The wound after device circumcision tends to be slightly wider than after surgical circumcision, with some healing by secondary intention.
- There is a need for men to abstain from sexual intercourse until the wound has completely healed, and this process takes at least one week longer with device circumcision. Men should be provided with condoms during the recovery period and advised to use condoms as soon as they resume intercourse because this will protect the newly healed wound.

A9.1.2. Devices prequalified by the World Health Organization

The World Health Organization reviews evidence to inform recommendations on the use of male circumcision methods as well as prequalification of a male circumcision device, which means that the device has undergone an assessment process to determine safety, acceptability, performance and quality of the manufacturing system (5). The device should be applied and removed in accordance with the manufacturer's instructions for use. Prequalification status of a device can be seen on the World Health Organization's website (6).

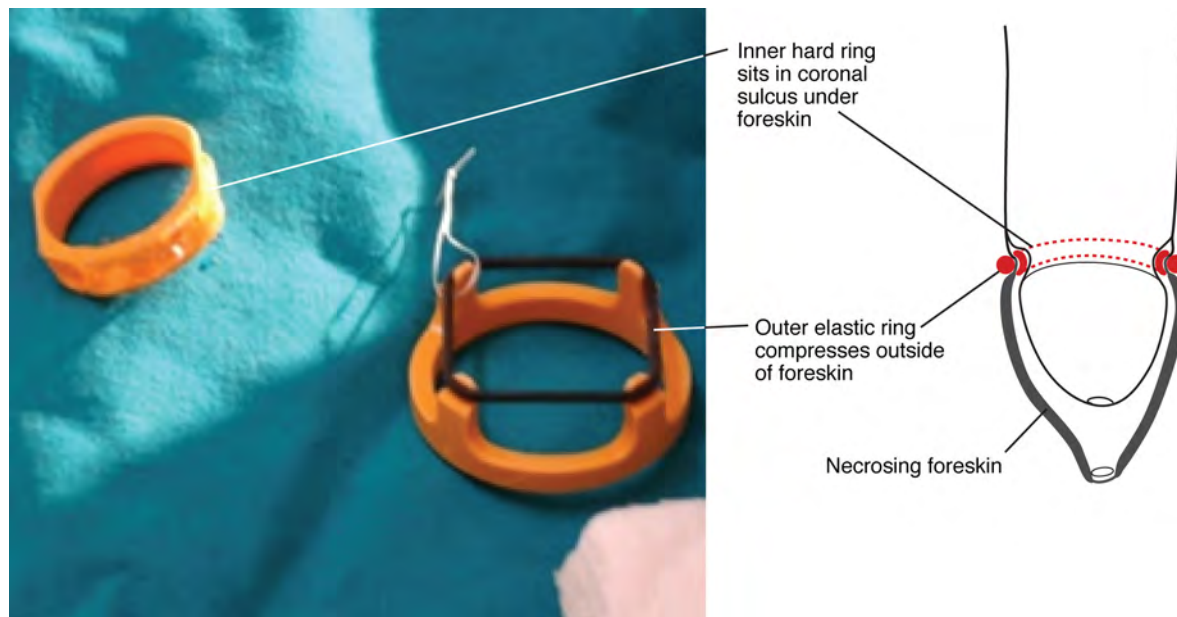
After a device has been designated as prequalified, there is continued monitoring (postmarket surveillance) of the device. From time to time, the manufacturer, in consultation with the World Health Organization, may make changes to the device instructions to improve the device's use. Also, if new risks or adverse events are identified, a field safety correction notice may be issued by the manufacturer and the instructions for use updated. This means that, at all times, the instructions for use issued by the manufacturer are kept current and should be referred to by all who provide conventional or device-based surgical circumcision. Providers in every clinic or facility should periodically review these instructions for any circumcision device they use. Each device comes with a set of instructions, and providers should always consult the latest version—not rely on older filed copies—because small improvements are constantly being made.

A9.1.3. Elastic collar compression device (see Fig. A9.1.1)

The elastic compression type of device cannot be used in circumcising clients with a very tight prepuce or where adhesions prevent full retraction of the foreskin. In practice, the device often cannot be used for younger adolescent boys because there is often a relatively tight prepuce and also physiological adhesions between the glans and foreskin. One study found about 50% of 13-year-old adolescent boys were ineligible for circumcision with this specific device method (7). The proportion of clients ineligible for circumcision with this device decreases with increasing age and maturity. Among eligible clients, this device is effective and safe, provided that the manufacturer's instructions for use are followed and the client is vaccinated against tetanus (8).

Generally, device application is quick and straightforward, and there is no need for immediate surgical backup at the time of the application. However, if the device displaces or the client removes his device, this can produce extreme penile swelling; in this situation, there is a need for backup surgical clinics or facilities within six to 12 hours of the problem becoming apparent. Severe swelling, including skin ulceration, is more likely if the device is displaced or removed more than six hours after but within the first 48–72 hours of its application (2). Device displacement after 72 hours is less likely to cause severe swelling, but there may be bleeding (2). Normally, the client has to return to the clinic six to seven days after the device was applied for the device to be removed. After device removal, wound healing takes about six additional weeks, and there is a need for wound care and dressing during this period.

Fig. A9.1.1. Elastic collar compression male circumcision device^a



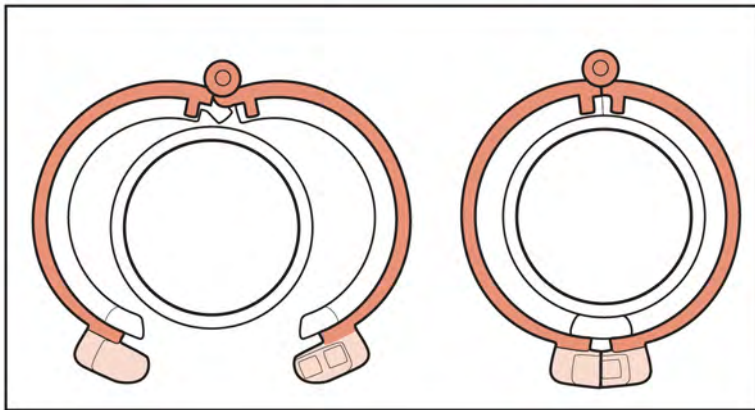
^a The photograph (left) shows the inner grooved ring (separate) and the outer elastic compression ring mounted on the device applicator. The drawing (right) shows the site of device placement in relation to the glans and foreskin. The device is worn for one week, and the device and foreskin are removed at a second visit that occurs one week after device placement.

A9.1.4. Collar clamp device (see Fig. A9.1.2)

The collar clamp device has been found to be safe for use in adolescents boys and men, provided that the manufacturer's instructions for use are followed. Refer to the manufacturer's instructions for use regarding age or other indications.

Because the foreskin is removed with this device at the time of its application, there is a need for surgical backup on site if the device slips off during or after the application procedure, and after the foreskin has been cut off. If this happens, there is an open wound and a need for immediate surgical haemostasis (Chapter 8, Section 8.4.1). If providers are well trained in applying the device, slippage during application is a rare event. Normally, the client has to return six to seven days after the device's application for its removal.

Fig. A9.1.2. Collar clamp male circumcision device



REFERENCES

1. Guideline on the use of devices for adult male circumcision for HIV prevention. Geneva: World Health Organization; 2013 (http://apps.who.int/iris/bitstream/10665/93178/1/9789241506267_eng.pdf, accessed 14 August 2017).
2. Population Services International (PSI), College of Surgeons of East, Central and Southern Africa (COSECSA), Centers for Disease Control and Prevention (CDC). Adverse event action guide for voluntary medical male circumcision by surgery or device, 2nd edition, August 2017 revision. PSI, COSECSA and CDC; 2016 (<https://www.malecircumcision.org/resource/adverse-event-action-guide-voluntary-medical-male-circumcision-surgery-or-device-2nd>, accessed 15 September 2017).
3. WHO guideline on the use of safety-engineered syringes for intramuscular, intradermal and subcutaneous injections in health care settings. Geneva: World Health Organization; 2016 (<http://apps.who.int/iris/bitstream/10665/250144/1/9789241549820-eng.pdf>, accessed 14 August 2017).
4. World Health Organization/Jhpiego. Manual for early infant male circumcision under local anaesthesia. Geneva: World Health Organization; 2010 (http://apps.who.int/iris/bitstream/10665/44478/1/9789241500753_eng.pdf, accessed 14 August 2017).
5. Overview of the prequalification of male circumcision devices assessment process: prequalification of male circumcision devices. World Health Organization; 2011 (http://www.who.int/diagnostics_laboratory/evaluations/111216_pqmc_007_overview_document.pdf?ua=1, accessed 14 August 2017).
6. WHO performance, quality and safety catalogue. World Health Organization; 2017 (http://apps.who.int/immunization_standards/vaccine_quality/pqs_catalogue/, accessed 14 August 2017).
7. Tshimanga M, Hatzold K, Mugurungi O, Mangwiro T, Ncube G, Xaba S, et al. Safety profile of PrePex male circumcision device and client satisfaction with adolescent males aged 13–17 years in Zimbabwe. *J Acquir Immune Defic Syndr.* 2016;72 Suppl 1:S36–42. doi: 10.1097/QAI.0000000000000799.
8. Tetanus and voluntary medical male circumcision: risk according to circumcision method and risk mitigation (report of the WHO technical advisory group, 12 August 2016). Geneva: World Health Organization; 2016 (<http://www.who.int/hiv/pub/malecircumcision/tetanus-vmmc-report/en/>, accessed 29 August 2017).

